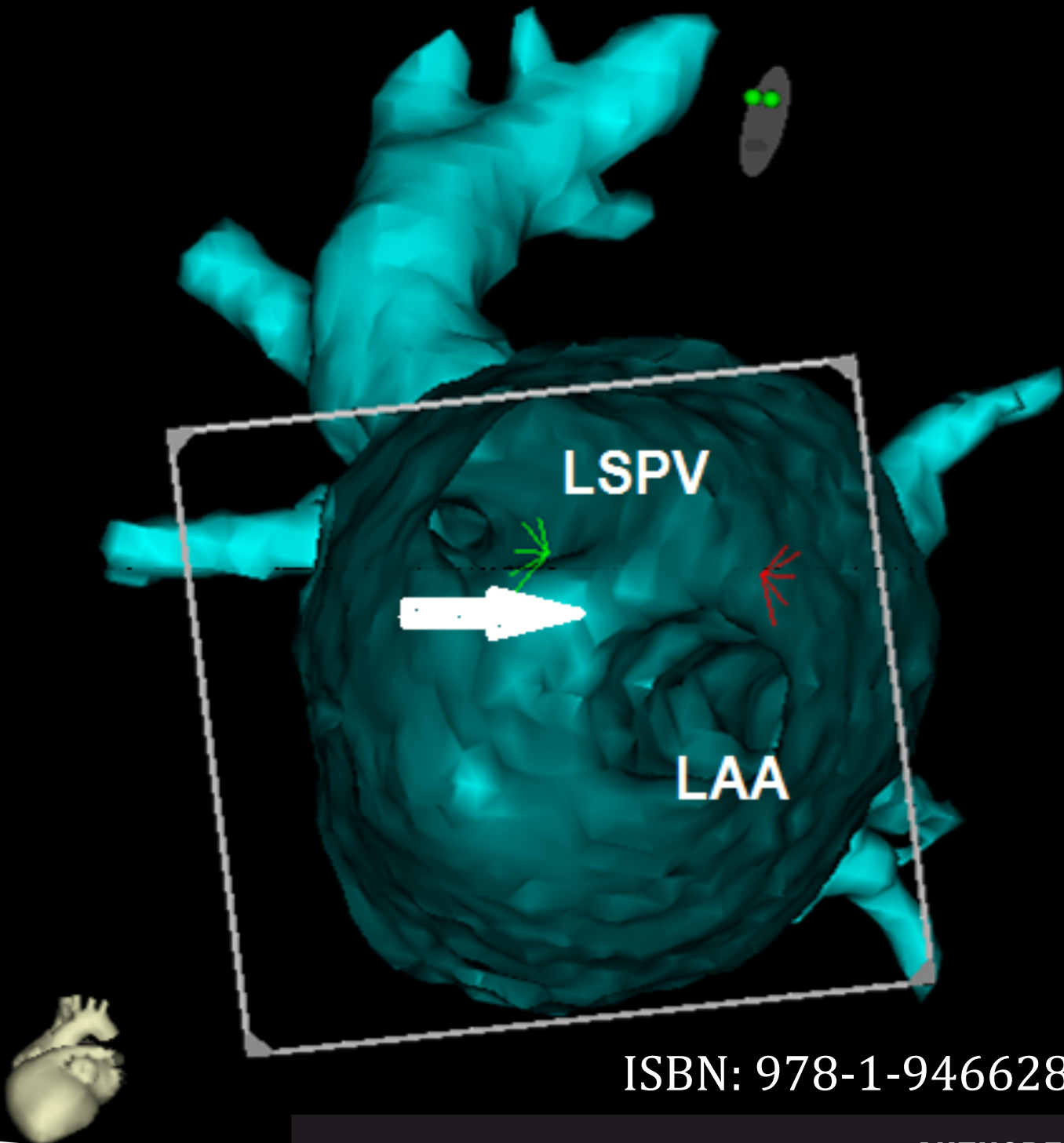


# AN ATLAS OF LEFT ATRIUM FOR ELECTROPHYSIOLOGY BEGINNERS



ISBN: 978-1-946628-17-6

**AUTHORED BY:  
CISMARU GABRIEL**

# An Atlas of Left Atrium for Electrophysiology Beginners

**Cismaru Gabriel\***


Department of Cardiology, Rehabilitation Hospital-Iuliu Hatieganu University of Medicine and Pharmacy,  
Romania

**\*Corresponding Author**

Department of Cardiology, Electrophysiological laboratory, Rehabilitation Hospital-Iuliu Hatieganu University  
of Medicine and Pharmacy, Cluj-Napoca, Romania

**Published By :**

Juniper publishers Inc.  
United States  
March 25, 2019



**Gabriel Cismaru M.D., Ph.D.,**

Dr. Cismaru Gabriel received his doctorate in medicine from the “Iuliu Hatieganu” University of Medicine and Pharmacy, Cluj- Napoca in 2016 and earned his MD degree from the same university in 2005. After completing his residency in cardiology, Dr. Cismaru began his electrophysiology fellowship at the Institute Lorrain du Coeur et des vaisseaux Louis Mathieu, Nancy-France. In 2011 started to work at the Electrophysiology Laboratory of the Rehabilitation Hospital Cluj-Napoca. He has authored or coauthored peer-reviewed articles, book chapters in the field of electrophysiology and cardiac pacing.

The new advances in cardiac arrhythmias techniques increased the success rate of complete treatment for patients suffering from arrhythmias. Catheter ablation of atrial fibrillation is routinely performed in EP centers. Knowing the anatomy of the left atrium is a cornerstone for the EP beginner. The topic is of great interest to electrophysiologists dealing with catheter ablation of all types of left atrial arrhythmias (atrial fibrillation, atrial tachycardia, atrial flutter, premature atrial contractions).

## List of Contents

S.No.	Content	Page No.
1	Foreword	5
2	Introduction	6
3	<b>Chapter 1: Anatomy of the Left Atrium</b>	<b>7-19</b>
3.1.	Gross anatomical structure of the left atrium	8-13
3.2.	Fossa ovalis	13-14
3.3.	Pulmonary veins	14-15
3.4.	The mitral isthmus	15
3.5.	Left atrial appendage	15-16
3.6.	Relationship of the left atrium with other anatomical structures esophagus	16-17
3.6.1.	The Phrenic Nerves	17
3.6.2.	Aorta	18-19
4	<b>Chapter 2: Ray Anatomy of the Left Atrium</b>	<b>20-26</b>
5	<b>Chapter 3: Transthoracic Echographic Anatomy of the Left Atrium</b>	<b>27-36</b>
6	<b>Chapter 4 : Transesophageal Echographic Anatomy of the Left Atrium</b>	<b>37-48</b>
7	<b>Chapter 5: Intracardiac Echographic Anatomy of the Left Atrium</b>	<b>49-71</b>
8	<b>Chapter 6: Computed Tomography of the Left Atrium</b>	<b>72-87</b>
9	<b>Chapter 7: Image integration</b>	<b>88-105</b>
10	Conclusion	105-106
11	References	106



## Foreword

The goal of electrophysiology education is to prevent and treat arrhythmias. In this regard, atrial fibrillation is the most rewarding arrhythmia to educate beginners, since it is very frequent and leads to thrombotic complications: stroke and acute limb ischemia. The cornerstone of atrial fibrillation ablation is left atrial anatomy.

The beginning electrophysiologist is frequently confronted by a paradox: diagrams that illustrate the left atrium in many arrhythmia books in a simplified, artwork, cartoon-like manner is easy to understand, but difficult to relate to the real anatomy. In turn anatomical photographs fail to show some important features and relationships with neighbouring structures. This atlas filled with echo and CT images was prepared to help bridge the gap between the more simplistic diagrams and the complex anatomical structure of the left atrium as seen on the anatomy table. CT images are in color because they were integrated with in three-dimensional mapping systems, and each heart chamber was colored differently.

The training of the young electrophysiologist is mostly focused of how to interpret electrograms and arrhythmia mechanisms. However, the origin of arrhythmias in specific structures of the heart chambers makes the anatomy of the heart the fundament of electrophysiologist. As the left atrium is the origin of atrial arrhythmias such as: focal atrial tachycardia, perimitral atrial flutter, atrial fibrillation, the book aims to review the anatomy of the left atrium as viewed during imaging examinations: echocardiography or computed tomography. A special chapter is dedicated to the image integration technique of the left atrial computed tomography which is widely used nowadays for catheter ablation of atrial fibrillation as it permits navigation inside the left atrium and pulmonary veins.

This book is dedicated to fellows in training and allied health professionals and not for experienced operators. If you think that the book is too easy for you, it means that you know already too much. It is not intended for experts in electrophysiology. Everybody wants to be an expert but forgets that several steps need to be made, and electrophysiology should be learned step by step without missing the beginner stage.

Being a beginner. What a wonderful thing to be! There is no need to look like you know everything. You have a long journey full of new things to discover.

Stop waiting. Start with the Beginner's Atlas.

## Introduction

Atrial fibrillation is an arrhythmia incompletely understood. Many cardiac diseases can lead to atrial fibrillation, and the pathogenesis of the arrhythmia is multifactorial. Newer techniques have developed for non-pharmacological treatment, like catheter-based radiofrequency ablation or cryoablation. The cornerstone of an ablation technique consists in targeting the junction between left atrium and pulmonary veins. Left atrium has different shapes depending on the diameter and volume from discoid if non-dilated to spherical in severe dilated forms and the pulmonary veins may present anomalies of shape and number making the ablation more difficult. We discuss in the following chapters the anatomy of the left atrium evaluated by different imagistic approaches: 2 D echo, transesophageal echo, intracardiac echo, computed tomography and detail the importance of the neighboring structures in the catheter ablation technique.

The left atrium modulates the left ventricular filling contributing to about 30% of the cardiac output. This function is particularly relevant for patients with congestive heart failure or in patients with diastolic heart failure.

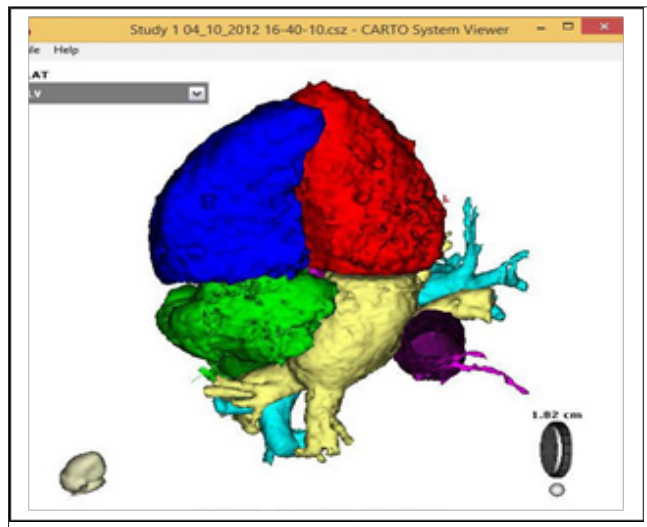
Because of the receptors that can be found at the atrial level it acts like a volume sensor, and also a “barometer” of the diastolic function of the left ventricle. The left atrium also secretes the natriuretic peptides and communicates with the renin-angiotensin-aldosterone system pathway. In the last years the left atrium was demonstrated to be a biomarker in cardiovascular diseases.

# Chapter 1

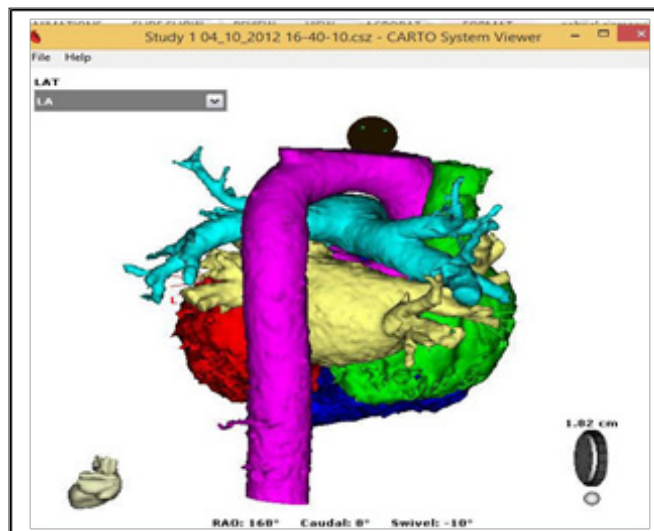
## Anatomy of the Left Atrium

### Gross anatomical structure of the left atrium

The left atrium is one of the 4 chambers of the heart: left ventricle, left atrium, right ventricle and right atrium (Figure 1.1). It is a posterior structure, that has anterior the left ventricle with the ascending aorta and posterior the descendant aorta. Superior to the left atrium the bifurcation of the pulmonary trunk can be seen, having 2 branches: left pulmonary artery and right pulmonary artery (Figure 1.2).



**Figure 1.1:** Three-D reconstruction of the left atrium, right atrium, left ventricle, right ventricle and aorta. From an inferior view the left atrium is in the posterior part of the left ventricle. Please note that LIPV is in contact with the descendant aorta and the RSPV is behind the superior vena cava.



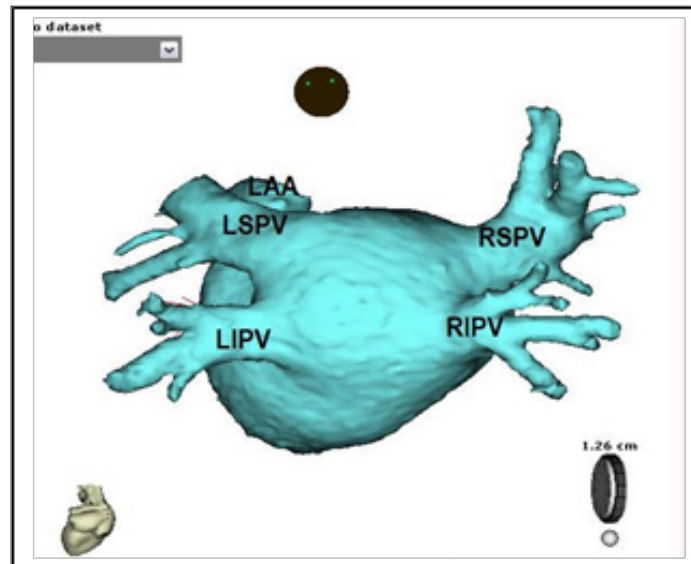
**Figure 1.2:** Three-D reconstruction of the heart and great vessels. From a posterior view, left atrium lies behind the left ventricle and aorta lies behind the left atrium. In fact, the left atrium is an anatomical structure between ascendant and descendant aorta. The RSPV is behind the superior vena cava and the LIPV in front of the descendant aorta. The left atrial appendage is near the left pulmonary artery.

The left atrium is derived from the primitive atrium, part of the heart tube. The single common pulmonary vein drains into the primitive atrium which expands taking parts from the vein. By evolution of the single pulmonary vein, 4 veins appear which open into the left atrium. This part of the LA derived from

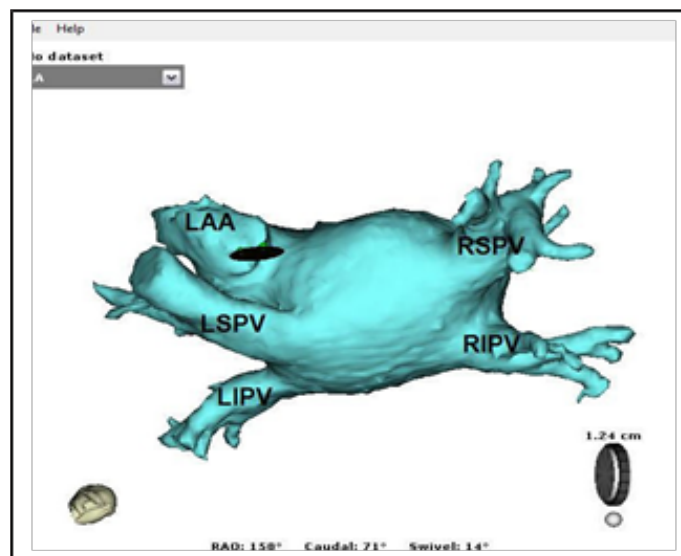
the primitive pulmonary vein remains smooth, while the left auricle becomes rough and trabeculated being derived from the primitive atrium.

The left atrium has 4 different parts:

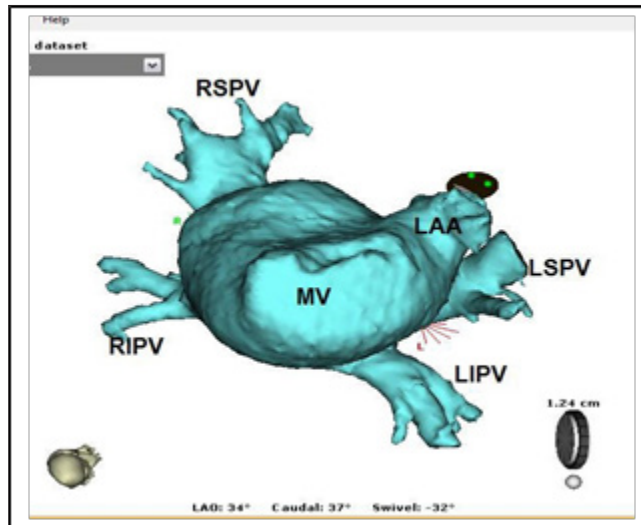
- a) the posterior part called venous part that receives blood from the four pulmonary veins;
- b) the vestibule which continues with the mitral ring and mitral valve;
- c) the left atrial appendage, a structure that is important for stroke prevention as most of the time at this level clot formation appears;
- d) the septal portion of the LA with the interatrial septum and the fossa ovalis (Figure 1.3-1.7). The left atrium presents 5 distinct walls: anterior, superior, lateral, septal and posterior. The anterior wall comes into contact with the posterior wall of the ascending aorta (Figure 1.8-1.14).



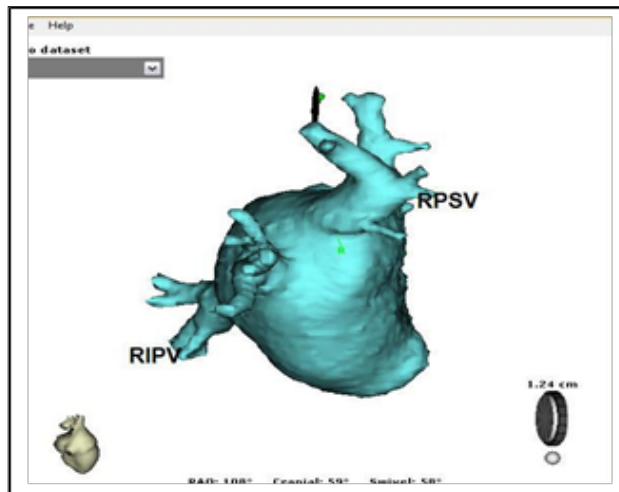
**Figure 1.3:** Posterior all the left atrium. Four veins are visible: 2 on the right side and 2 on the left side. Superior veins have a larger diameter compared to inferior veins. In the anterior region of the left atrium, LAA is present.



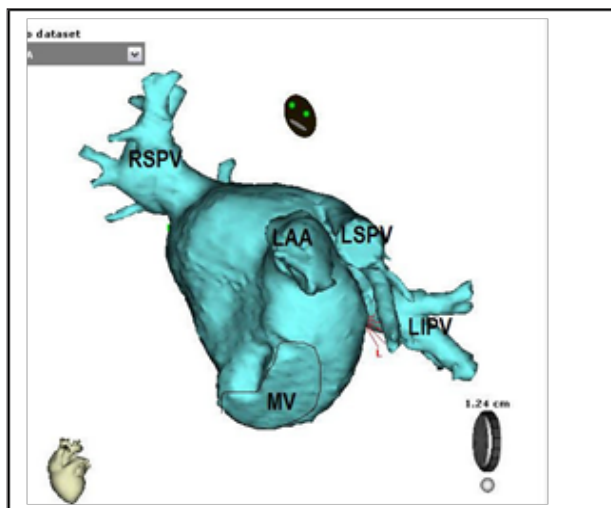
**Figure 1.4:** Three-D reconstruction of the left atrium. Superior view. The left atrial appendage is an anterior structure; it can be seen in front of the LSPV.



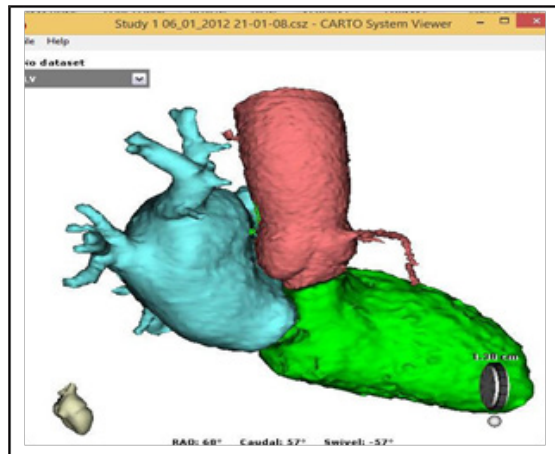
**Figure 1.5:** Three D reconstruction of the left atrium. Anterior wall of the L. In front of the image the mitral valve can be seen. Mitral annulus has 2 important diameters: a latero-lateral diameter and an antero-posterior diameter.



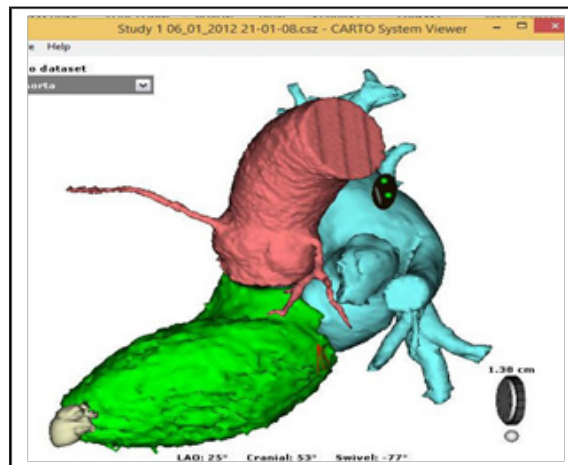
**Figure 1.6:** Three-D reconstruction of the left atrium. Septal wall of the LA represented by the interatrial septum and fossa ovalis. Please note the distance between RSPV and mitral ring which is longer than the distance between RIPV and the mitral ring.



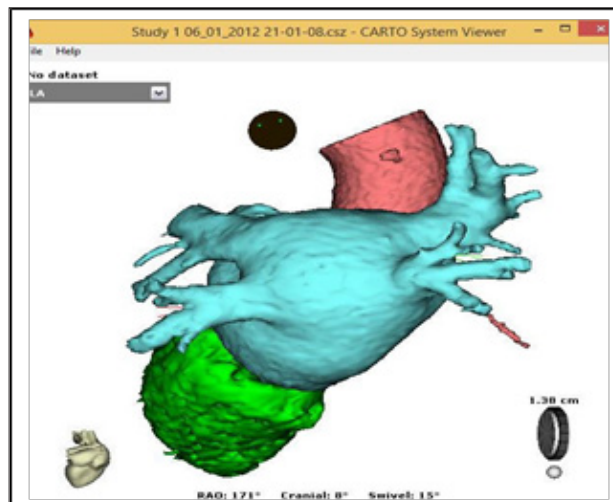
**Figure 1.7:** Three-D reconstruction of the left atrium. The lateral wall seen from left lateral view. The LIPV drains perpendicularly on the posterior wall of LA. LSPV is a more anterior structure compared to LIPV.



**Figure 1.8:** Computed tomography of the left atrium. Three-D reconstruction of the left atrium, left ventricle and aorta. Right anterior oblique view 58°, caudal tilt 57° and swivel -77°. From a lateral view the left atrium which is not dilated has a discoid shape and is situated posterior to the ascendant aorta being in direct contact with the aortic root, close to the non-coronary cusp.

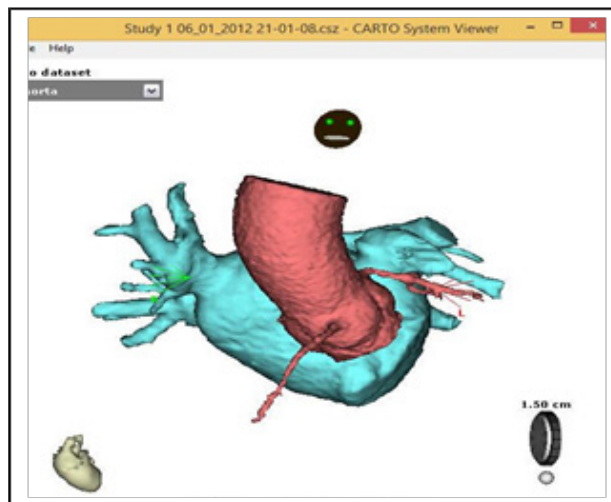


**Figure 1.9:** Computed tomography of the left atrium. Three-D reconstruction of the left atrium, left ventricle and aorta. Left anterior oblique view 25°, cranial tilt 53° and swivel -77°. From a lateral view the left atrium which is not dilated has a discoid shape and is situated posterior to the ascendant aorta. The bifurcation of the left coronary artery is in close proximity to the left atrial appendage.

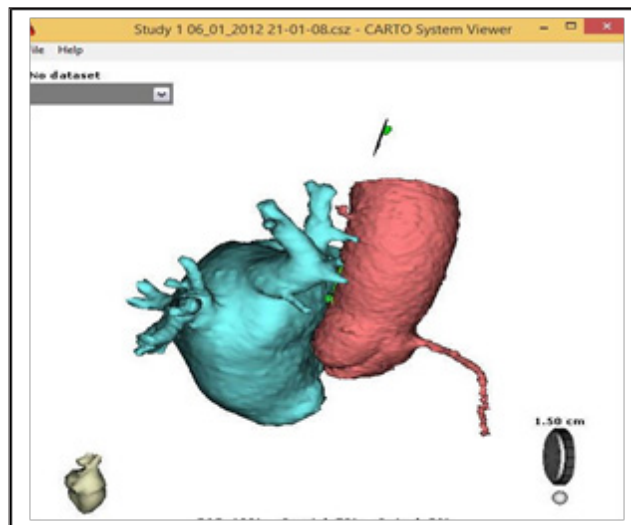


**Figure 1.10:** Computed tomography of the left atrium. Three-D reconstruction of the left atrium, left ventricle and aorta. Right anterior oblique view 171°, cranial tilt 8° and swivel 15°. The left atrium is a posterior structure, behind the left ventricle. Ascendant aorta is anterior to the left atrium.

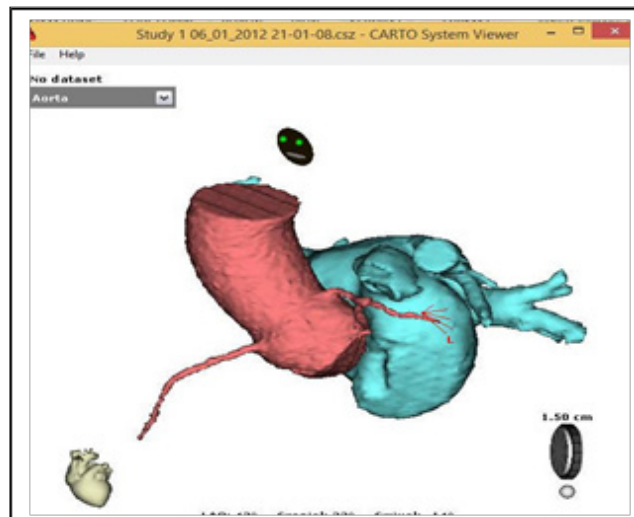




**Figure 1.11:** Computed tomography of the left atrium. Three-D reconstruction of the left atrium, and aorta. Right anterior oblique view 10°, cranial tilt 14° and swivel -3°. The left atrium which is situated posterior to the ascendant aorta.

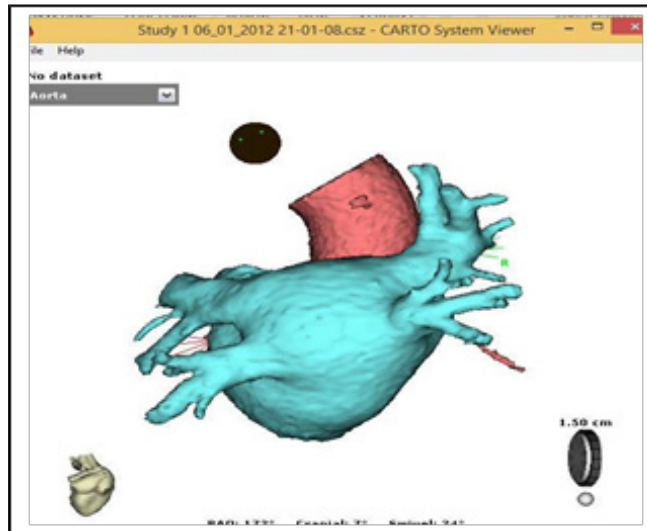


**Figure 1.12:** Computed tomography of the left atrium. Three-D reconstruction of the left atrium, and aorta. Right anterior oblique view 100°, cranial tilt 72° and swivel 56°. The left atrium which is situated posterior to the ascendant aorta.



**Figure 1.13:** Computed tomography of the left atrium. Three-D reconstruction of the left atrium, and aorta. Left anterior oblique view 43°, cranial tilt 33° and swivel -14°. The left atrium which is situated posterior to the ascendant aorta. The left atrium has a discoid shape.



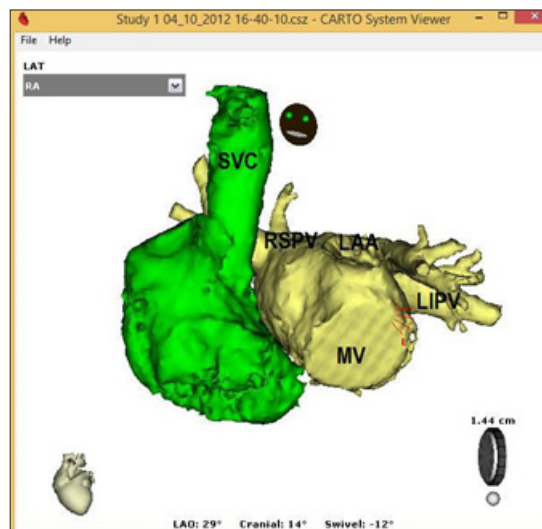


**Figure 1.14:** Computed tomography of the left atrium. Three-D reconstruction of the left atrium, and aorta. Right anterior oblique view 172°, cranial tilt 7° and swivel 24°. The left atrium which is situated posterior to the ascendant aorta.

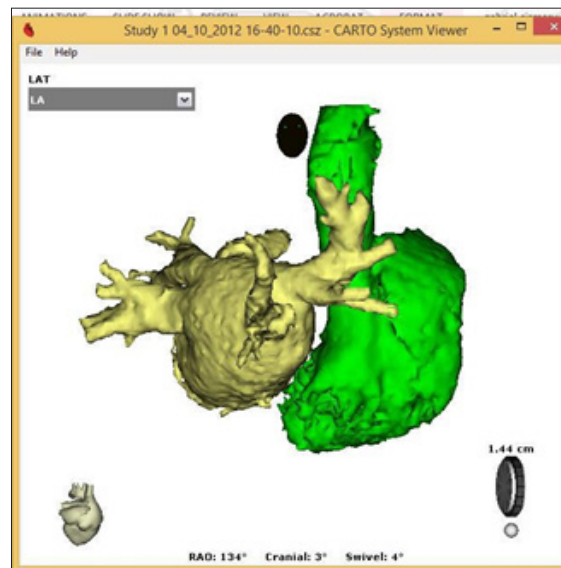
The diameter of the left atrium increases with the duration of the left atrium. Normally is lower than 40mm antero-posteriorly, but in permanent forms of AF can increase over 70mm.

## Fossa ovalis

The real interatrial septum is located at the level of fossa ovalis. The rest of the muscular septum is called the interatrial groove being an invagination of the left myocardium and right myocardium separated by fibrofatty tissue. Therefore, the transeptal puncture should be performed at the level of the fossa ovalis, because a puncture through the interatrial groove may produce bleeding inside the pericardium especially in highly anticoagulated patients. The angle of the fossa ovalis with the horizontal plane is 45 to 60 degrees, and this may be variable in cases with important dilation of the left atrium (Figure 1.15 & 1.16). In cases with Marfan syndrome, aortic aneurysm, kyphoscoliosis or pleural effusion, the angle is changed, and the fossa displaced the best way of performing transeptal puncture being with the help of intracardiac ultrasound.



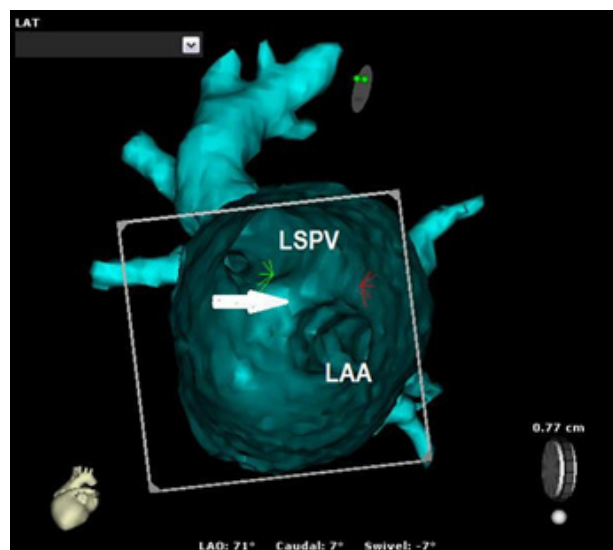
**Figure 1.15:** Computed tomography of the left atrium. Three-D reconstruction of the right atrium (green) and left atrium (yellow). Left anterior oblique view 29° with cranial tilt 14° and swivel -12°. Please note the angle of the interatrial septum between the right atrium and the left atrium. At this level transeptal puncture is performed. From the LAO view the mitral valve and tricuspid valve look directly towards the examination. The left atrium is discoid when is not dilated and ovoid when is severely enlarged. SVC=superior vena cava; MV=mitral valve; LIPV=left inferior pulmonary vein; RSPV=right superior pulmonary vein; LAA=left atrial appendage.



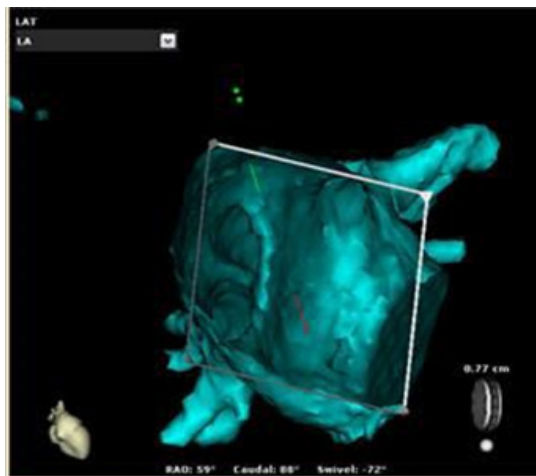
**Figure 1.16:** Computed tomography of the left atrium. Three-D reconstruction of the right atrium (green) and left atrium (yellow). Right anterior oblique view 134° with cranial tilt 3° and swivel 4°. The space between the left atrium and the right atrium is called interatrial groove, being an invagination of the myocardium with fibrofatty tissue. The “real interatrial space” is at the level of the fossa ovalis which has a 50° angle with the horizontal plane.

## Pulmonary veins

The normal anatomy of the left atrium consists of 4 pulmonary veins that drain in 4 different pulmonary ostia. Pulmonary vein ostia are ellipsoid in shape with the supero-inferior diameter being greater than the antero-posterior diameter. Usually the superior venous ostia are larger than the inferior venous ostia [1]. The isthmus between the inferior and superior left pulmonary veins is called the carina. Myocardial fibers pass at this level the zone being important for PV isolation. The isthmus between the left superior pulmonary vein and the left atrial appendage, with important myocardial fibers passing at this level is called the ridge which is also a structure difficult to ablate, necessitating stable catheter contact (Figure 1.17 & 1.18). Most of the time the LAA orifice is located superior to the LSPV, but sometimes can be located inferiorly. At the level of the ridge between the LAA and LSPV runs the oblique vein of Marshall which is a remnant of the left superior caval vein, together with nerve bundles and small arteries.



**Figure 1.17:** “Clipping plane” is a dedicated tool that permits to visualize inside the left atrium. In this image the ridge between LAA and left pulmonary veins are visible. Left pulmonary veins have a common ostium at the level of the left atrium, though separated between them with an infold.



**Figure 1.18:** The “clipping plane” permits to monitor the contact of the ablation catheter with the ridge (white arrow) between the LAA and left superior pulmonary vein. (LAA= left atrial appendage; LSPV=left superior pulmonary vein).

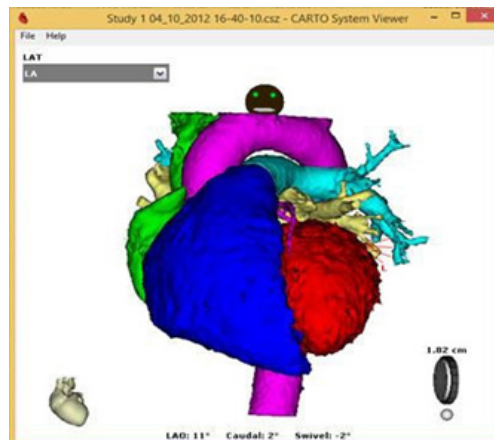
Myocardial sleeves are sources of triggers that initiate atrial fibrillation. Anatomical variations of the pulmonary veins consist in: common trunk of both left pulmonary veins, accessory middle right pulmonary veins, roof vein. The first attempts of catheter ablation aimed to destroy the triggers inside the pulmonary veins, but this approach complicated with pulmonary vein stenosis. The recent approach is to isolate the veins at the level of the left atrium in the antral zone.

### The mitral isthmus

The mitral isthmus is the region between the LIPV and mitral annulus. It is important structure that can be ablated in persistent form of AF when performing lines inside the left atrium. It is essential for treating or preventing macro reentry around the mitral annulus.

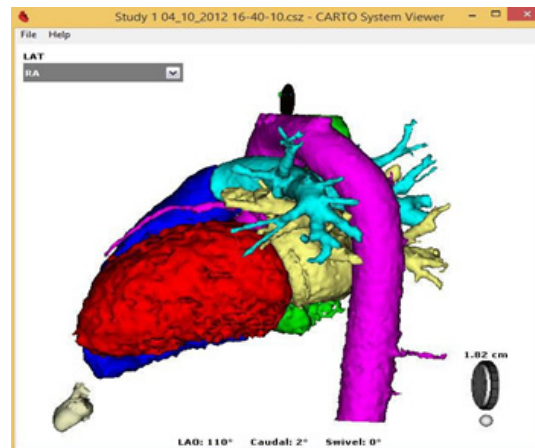
In patients with persistent form of atrial fibrillation, additional ablation lines may be necessary to achieve sinus rhythm restauration. In the study of Cho et al. [2] with computed tomography imaging, anatomical characteristics of three different lines were assessed: the anteromedial (AM), anterolateral (AL), and posterolateral (PL) left atrial lines, from: right superior, left superior, and left inferior pulmonary vein ostia, respectively. The authors showed that the PL lines were shortest among the three lines and closest to the left circumflex artery and the great cardiac vein of the coronary sinus. Left atrial myocardium was thickest at the level of AL line, and the sinus node artery was frequently found at the level of AM and AL lines [2].

### Left atrial appendage



**Figure 1.19:** Computed tomography of the left atrium. Three-D reconstruction of the left atrium, right atrium, left ventricle, right ventricle and aorta. Left anterior oblique view 11° with caudal tilt 2° and swivel -2°. The left atrium is a posterior structure behind the left ventricle. The left atrial appendage meets the pulmonary trunk and left pulmonary artery.

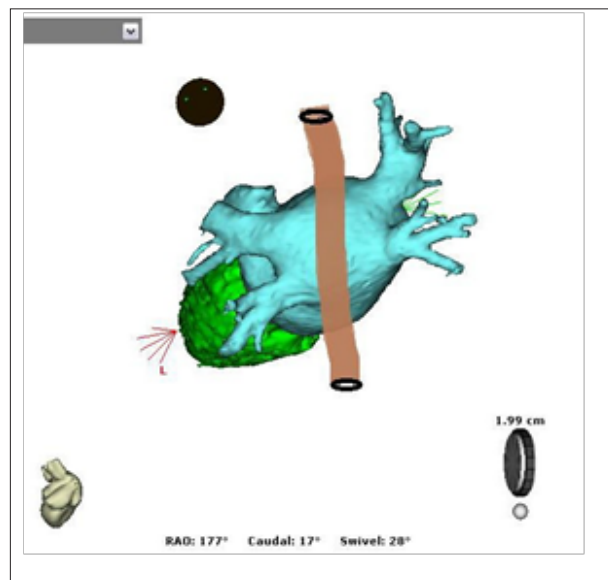
Left atrial appendage can also be a source of triggers for atrial fibrillation and sometimes isolation of LAA may be efficient in persistent form of AF [3]. LAA is a multilobulated finger-like structure, with the tip pointing anteriorly, posteriorly or medially (Figure 1.19 & 1.20). In the study of Di Biase L [3] morphology was characterized by: cactus shape, chicken wing, windsock and cauliflower. The highest thromboembolic risk is given by the chicken wing morphology. The ostium of the LAA is either elliptical or round. The interior of the LAA is non-smooth, given by the presence of pectinate muscles.



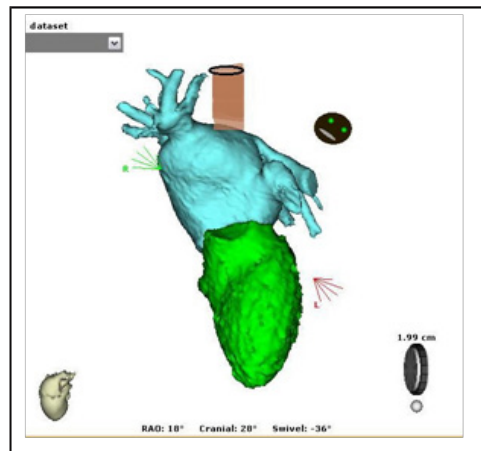
**Figure 1.20:** Computed tomography of the left atrium. Three-D reconstruction of the left atrium, right atrium, left ventricle, right ventricle and aorta. Left anterior oblique view 110° with caudal tilt 2° and swivel 0°. From the left lateral view the left atrium is between the ascendant aorta and descendant aorta. The LIPV comes in direct contact with the descendant aorta and the LSPV with the left pulmonary artery. The left atrial appendage has an anterior orientation towards the mitral.

## Relationship of the left atrium with other anatomical structures esophagus

The posterior wall of the left atrium meets the anterior wall of the esophagus. Therefore, pain in the thorax or abdomen may complicate ablation of the posterior wall of the left atrium. The course of the esophagus may be variable: sometimes it meets the middle of the posterior left atrial wall, or with the right or left veno-atrial junction (Figure 1.21 & 1.22). Between the esophagus and left atrium fibrous pericardium and fibro-fatty tissue is present.

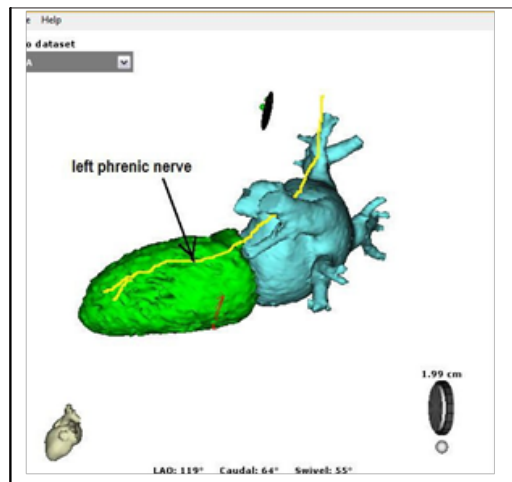


**Figure 1.21:** Computed tomography of the left atrium. Three-D reconstruction of the left atrium, and left ventricle. Right anterior oblique view 177°, caudal tilt 17° and swivel 28°. The left atrium is situated posterior to the ventricle. The esophagus is posterior to the left atrium. It can move between the left and right veins.

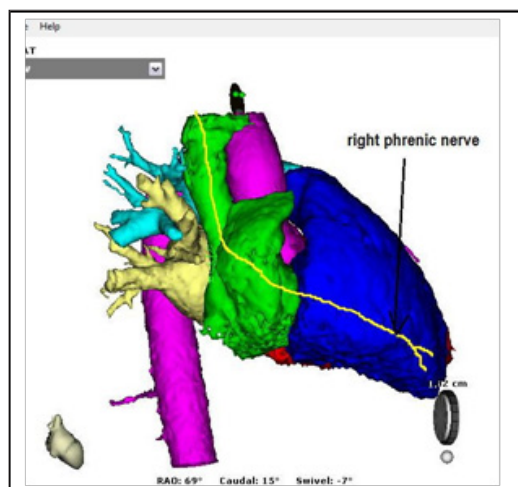


**Figure 1.22:** Computed tomography of the left atrium. Three-D reconstruction of the left atrium, and left ventricle. Right anterior oblique view 18°, cranial tilt 28° and swivel -36°. The left atrium is situated posterior to the left ventricle. Please note that the left veins are closer to the mitral ring compared to the right veins.

The Phrenic Nerves: The right phrenic nerve lies near the superior vena cava and superior right pulmonary vein. The left phrenic nerve lies close to the left atrial appendage body (Figure 1.23 & 1.24).



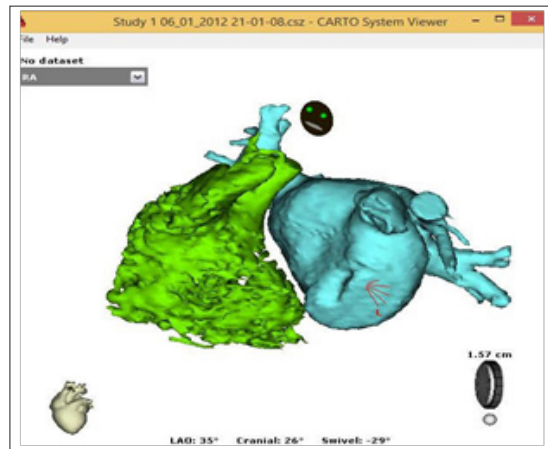
**Figure 1.23:** Computed tomography of the left atrium. Three-D reconstruction of the left atrium, and left ventricle. Left anterior oblique view 119°, caudal tilt 64° and swivel 55°. The left phrenic nerve is marked with yellow color.



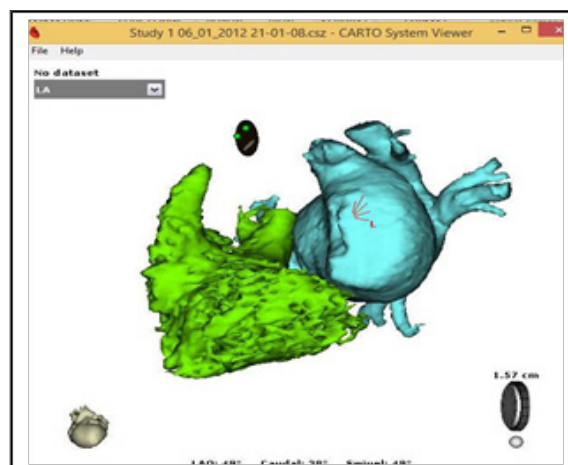
**Figure 1.24:** Computed tomography of the left atrium. Three-D reconstruction of the left atrium, right atrium, left ventricle, right ventricle and aorta. Right anterior oblique view 69° with caudal tilt 15° and swivel -7°. The right phrenic nerve is marked with yellow color.



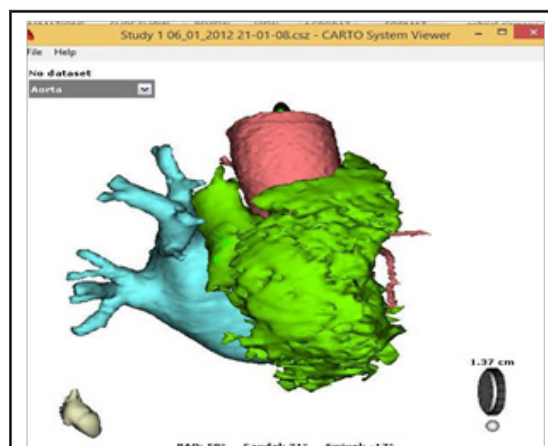
**Aorta:** The aorta is anterior to both atria. It lies in the space between the right and left atrium (Figure 1.25 & 1.26). During transeptal puncture, when passing from right to left atrium, the needle should not be oriented anteriorly towards the aorta because puncture accidents may appear. The right coronary artery flows near the base of the right atrial appendage and the left coronary artery near the base of left atrial appendage (Figure 1.27-1.29).



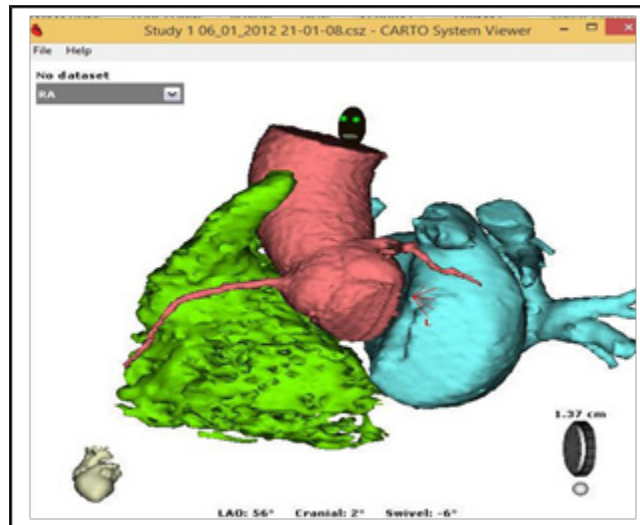
**Figure 1.25:** Computed tomography of the left atrium. Three-D reconstruction of the left atrium and right atrium. Left anterior oblique view 35°, cranial tilt 26° and swivel -29°. The space between the left atrium and right atrium is called interatrial groove, full of adipose tissue and small coronary vessels. Anterior to both atria is the place of the ascending aorta.



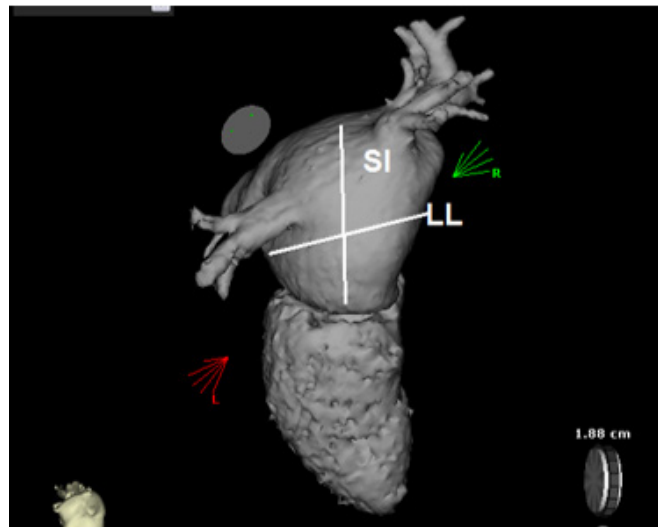
**Figure 1.26:** Computed tomography of the left atrium. Three-D reconstruction of the left atrium and right atrium. Left anterior oblique view 49°, caudal tilt 38° and swivel 49°. Anterior to both atria is the place of the ascending aorta.



**Figure 1.27:** Aorta lies between the 2 atria. The right coronary artery can be found at the base of the RAA.



**Figure 1.28:** Computed tomography of the left atrium. Three-D reconstruction of the right atrium, left atrium and aorta. Left anterior oblique view 56°, cranial tilt 2° and swivel -6°. Please note the position of both atrial appendages: LAA is close to the bifurcation of the left coronary artery. The right coronary artery can be found at the base of the RAA.



**Figure 1.29:** Computer tomography of the left atrium and left ventricle. Two of the 3 diameters of the left atrium are shown in the image: latero-lateral (LL) and supero-inferior (SI).

Please note that the long axis of the left atrium is not in the same plane with the long axis of the left ventricle.

# Chapter 2

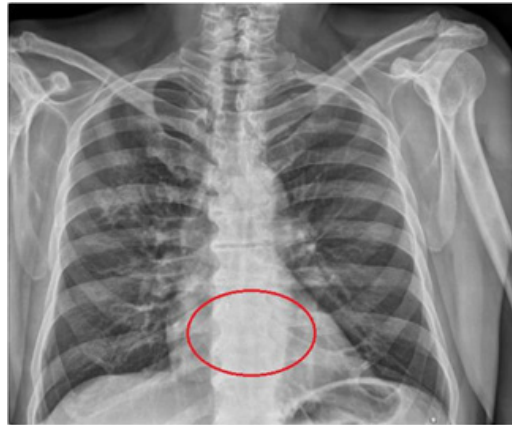


## X-ray Anatomy of the Left Atrium

Although left atrial quantification is mostly done with echocardiography, the high number of X-rays performed implies that cardiologists should confidently identify left atrial enlargement on chest X-ray.

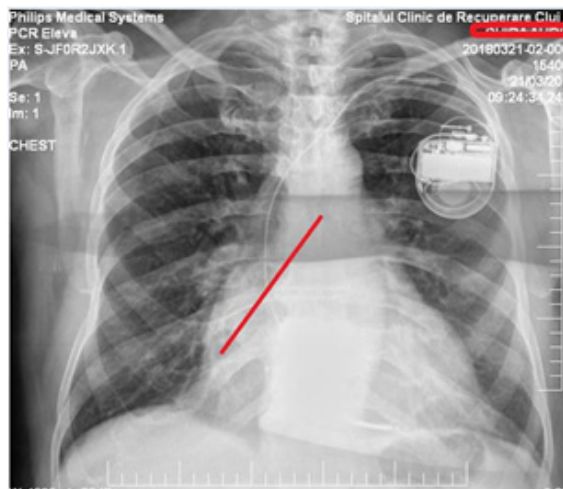
Even if the heart is a three-dimensional structure, X-ray visualizes it in 2 dimensions. The most used incidences in fluoroscopy are postero-anterior, left anterior oblique –LAO and right anterior oblique-RAO. In the PA view, the right border of the heart is given by the superior vena cava in the upper region and by the right atrium in the inferior region. The left border of the heart is given by the aortic arch, the left atrial appendage and the common pulmonary artery that for the gulf of the heart and anterior wall of the left ventricle.

Normally the left atrium cannot be seen on a chest X-ray because it is a posterior structure that locates behind the other 3 cardiac structures: left ventricle, right ventricle and right atrium (Figure 2.1). In cases of left atrial dilation, the left atrium becomes evident by several X-ray signs:



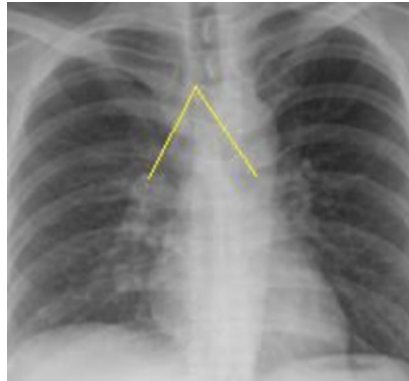
**Figure 2.1:** Standard thoracic radiograph obtained in the posteroanterior projection. The left atrium is a posterior structure that cannot be seen in a standard PA projection if is not dilated.

- a) Double density sign-the right side of the left atrium exerts force on the adjacent right lung and becomes visible when superimposed over the right border of the right atrium.
- b) Distance between the right border of the left atrium and the left bronchus over 70mm (Figure 2.2).

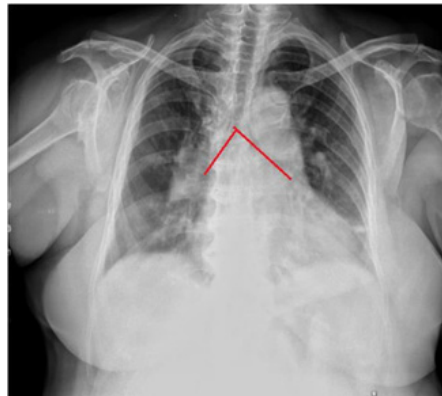


**Figure 2.2:** Standard thoracic radiograph obtained in the posteroanterior projection. The distance between the lateral wall of the atrium and the left bronchi's can be measured. It is over 70mm in case of a dilated LA.

- c) Disappearance of the left heart border concavity by dilation of the left atrial appendage.
- d) Increase of the tracheal bifurcation angle over 90 degrees (Figure 2.3 & 2.4).



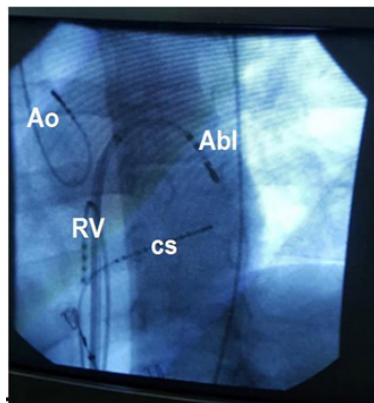
**Figure 2.3:** Standard thoracic radiograph obtained in the posteroanterior projection. Angle between the right and left bronchus in a patient with a non-dilated left atrium.



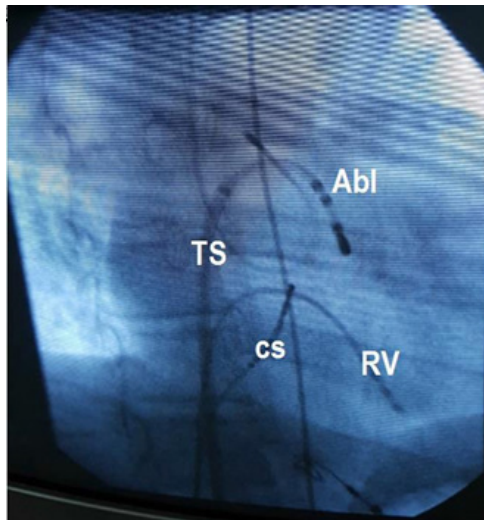
**Figure 2.4:** Standard thoracic radiograph obtained in the posteroanterior projection. Angle between the right and left bronchus in a patient with a dilated left atrium.

- e) Posterior displacement of the esophagus when filled with barium or of a naso-gastric tube.

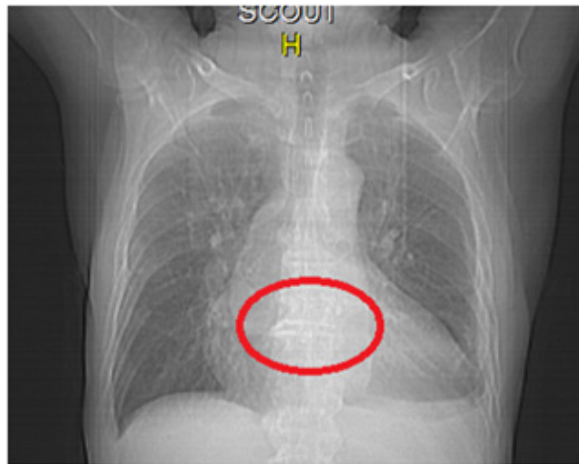
Catheter ablation procedures can be performed under X-ray guiding. It shows the exact position of the catheter inside the left atrium, the contact with the walls and the movement in different structures: pulmonary veins, appendage, mitral valve (Figure 2.5 -2.15). With the use of three- dimensional mapping systems, X rays are less and less used.



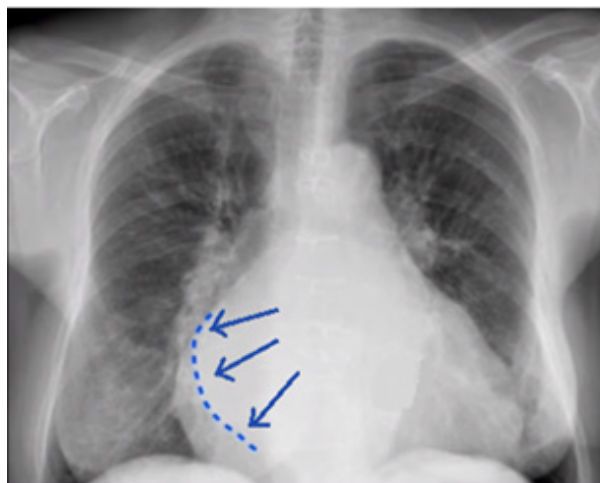
**Figure 2.5:** Chest X-ray during pulmonary vein isolation. Left anterior oblique view. The transseptal sheath is passing through the interatrial septum at the level of left atrium. The ablation catheter comes out of the transseptal sheath and is against the lateral wall of the left atrium. Other 2 diagnostic catheters are visible on the X-Ray image: coronary sinus catheter and right ventricular catheter. TS=transseptal sheath; Abl=ablation catheter; cs=coronary sinus; RV=right ventricular; Ao= catheter in the aorta.



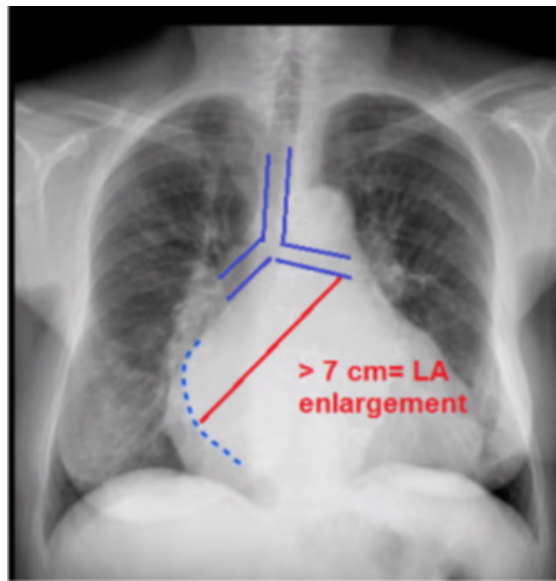
**Figure 2.6:** Chest X-ray during pulmonary vein isolation. Right anterior oblique view. The transseptal sheath is passing thorough the interatrial septum at the level of left atrium. The ablation catheter comes out of the transseptal sheath and is against the lateral wall of the left atrium. Other 2 diagnostic catheters are visible on the X-Ray image: coronary sinus catheter and right ventricular catheter. TS=transseptal sheath; Abl=ablation catheter; cs=coronary sinus; RV=right ventricular.



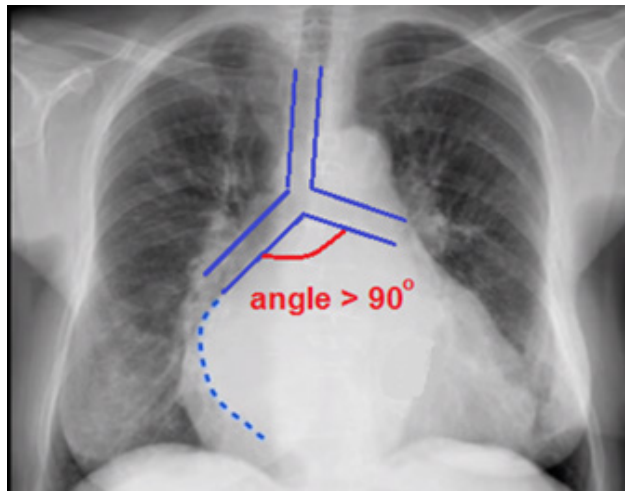
**Figure 2.7:** Chest X-ray of the thorax. PA view. The left atrium is a posterior structure that cannot be visualized in a standard X-ray if not dilated. Figure



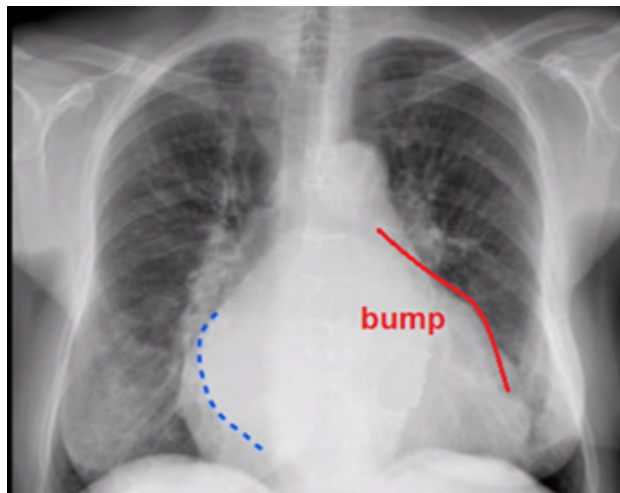
**Figure 2.8:** Chest X-ray of the thorax. PA view. Double density sign in a patient with enlarged left atrium due to significant mitral regurgitation.



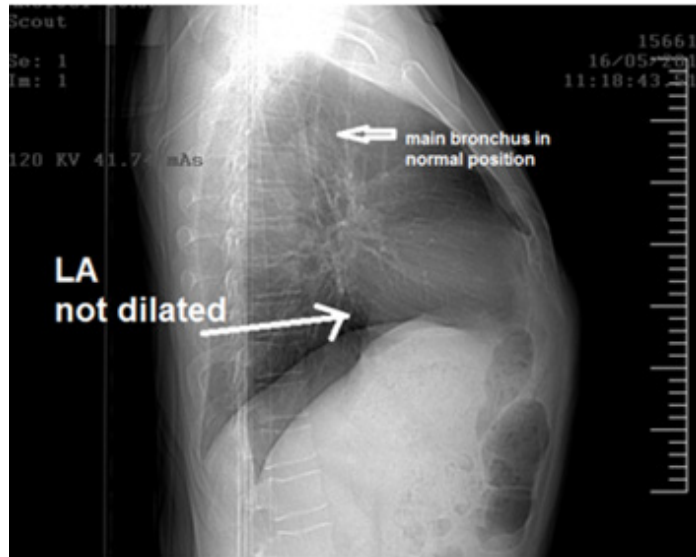
**Figure 2.9:** Chest X-ray of the thorax. PA view. Dilation of the left atrium. Distance between the left main bronchus and the lateral wall of the left atrium  $> 7$  cm.



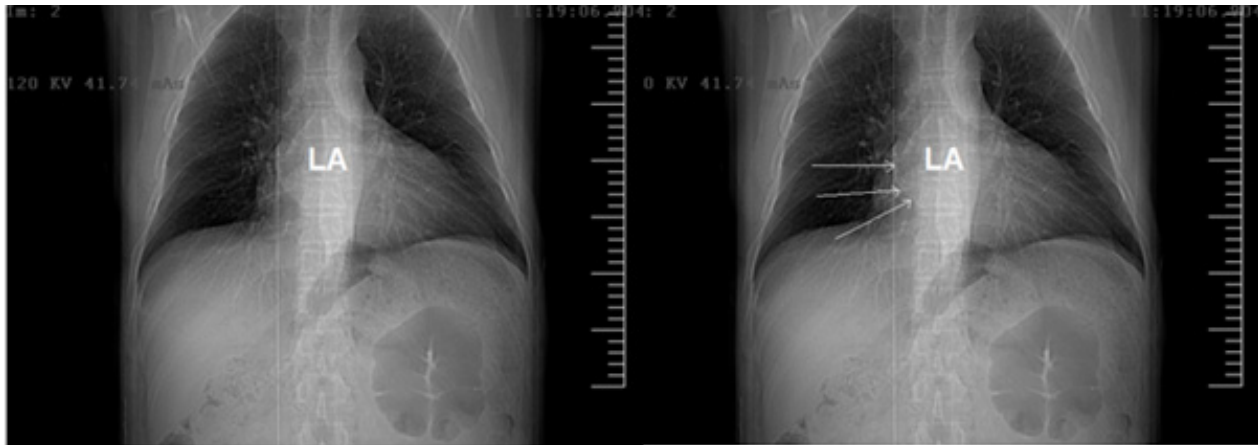
**Figure 2.10:** Chest X-ray of the thorax. PA view. Left atrial dilation. Angle between the right main bronchus and the left main bronchus  $> 90^\circ$ .



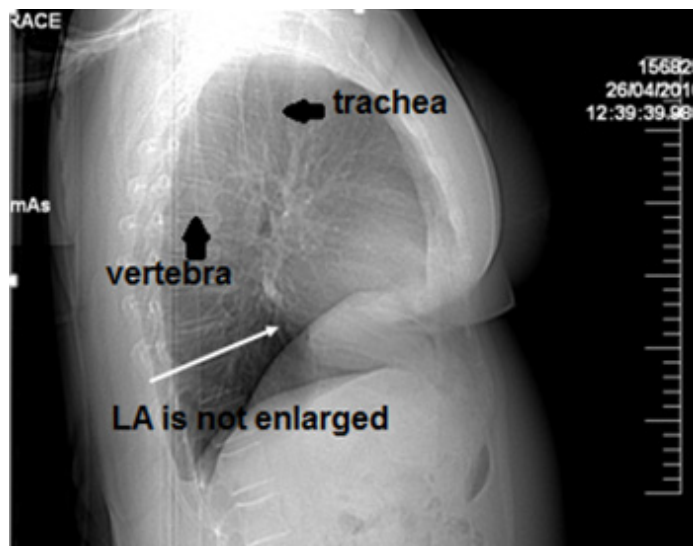
**Figure 2.11:** Chest X-ray of the thorax. PA view. Left atrial dilation leads to a bumping or convex image of the gulf of the heart.



**Figure 2.12:** Chest X-ray of the thorax. Lateral view. The left atrium is a posterior structure and in case of dilation it will modify the position of the main bronchus. In this image LA is not dilated and the main bronchus is in normal position.

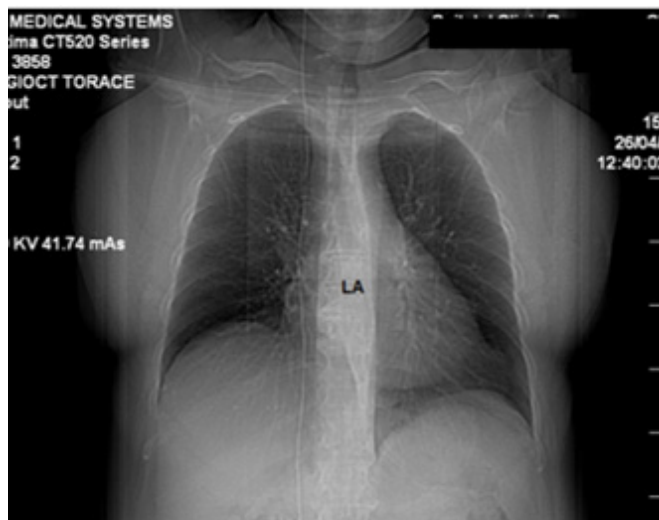


**Figure 2.13:** Chest X-ray of the thorax. PA view. "Double density" sign given by a mild dilation of the left atrium.



**Figure 2.14:** Chest X-ray of the thorax. Lateral view. The left atrium is a posterior structure and in case of dilation it will modify the position of the main bronchus. In this image LA is not dilated and the main bronchus is in a normal position.





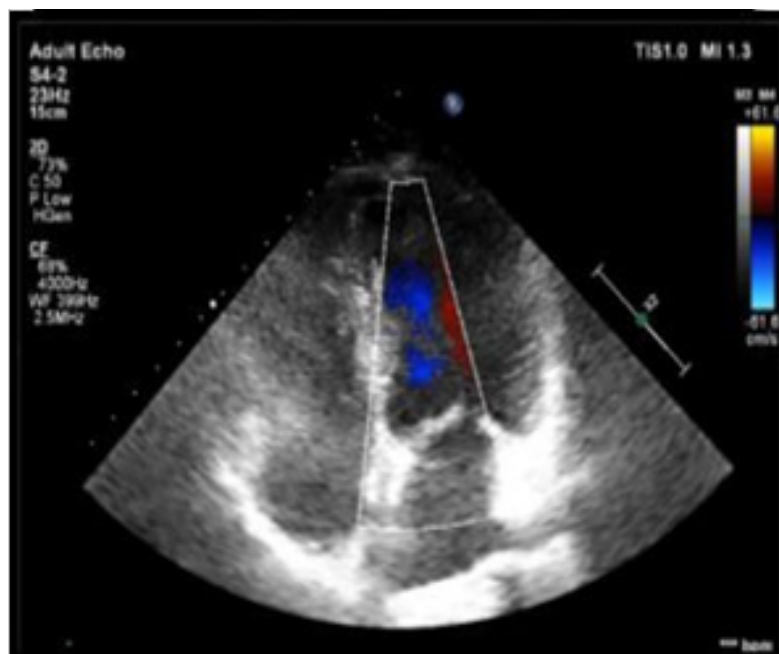
**Figure 2.15:** Chest X-ray of the thorax. PA view. The left atrium is a posterior structure and cannot be seen on a PA X-ray. It will be visible in case of dilation.

# Chapter 3

## Transthoracic Echographic Anatomy of the Left Atrium

Transthoracic echocardiography is one of the most used techniques in clinical practice. One of the first standardizes parameters of the left atrium in transthoracic echocardiography was the left atrial antero-posterior diameter. Historically we used the left atrium diameter that can be measured using the M-mode. But the left atrium enlarges asymmetrically this is why we need to use the volume of the LA. Furthermore, it was demonstrated by cardiac MRI that the longest axis of the left ventricle does not align with the longest axis of the left atrium. Therefore, when measuring the left atrium, we must maximize the diameter, meaning that the maximum LV diameter will be lost. The best parameter that evaluates the left atrium is the 2D volume, using either the surface-length formula or the modified Simpsons analysis. The last achievement in LA echography is 3 D echo which better approximates the volume of the chamber. After we obtain the volume of the left atrium, it should be indexed to the patient's gender and body size.

LA size is an important predictor for cardiovascular morbidity and mortality [4]. Patients with a dilated left atrium over 40mm had a higher risk of cardiovascular events [5]. Optimal assessment of LA size should include LA volume as LA diameter tend to underestimate the real size especially in case of dilation. There are several methods to measure the left atrial volume depending on the estimation method of geometry: spherical or ellipsoid geometry. It is also important to evaluate both systolic and diastolic dysfunction of the left ventricle when evaluating the left atrium (Figure 3.1-3.8). According to the 2015 Recommendations of Cardiac Chamber Quantification by Echocardiography in adults -an update of the American Society of Echography and the European Association of Cardiovascular Imaging, the normal volume of the left atrium is below  $34\text{ml/m}^2$  (the previous value was  $<28\text{ml/m}^2$ ). The preferred method for assessment is the modified Simpsons biplane which is more accurate and with fewer geometric assumptions than the area-length method. A mild dilation of the left atrium is given by a volume of  $34$  to  $41\text{ml/m}^2$ , moderate dilation between  $42$ - $48\text{ml/m}^2$  and severe  $> 48\text{ml/m}^2$ . Three-D echocardiography is more accurate compared to cardiac MRI and with superior prognostic ability but lacks normative data.



**Figure 3.1:** Bidimensional echocardiography, apical view, color doppler. In this patient with a left atrium of 38mm antero-posterior diameter there is no mitral regurgitation.



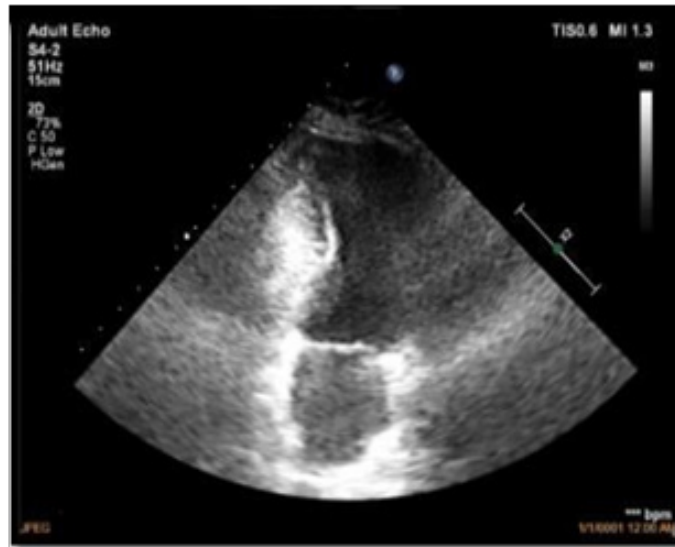


Figure 3.2: Bidimensional echocardiography, apical view. In this view the area of the left atrium can be measured.

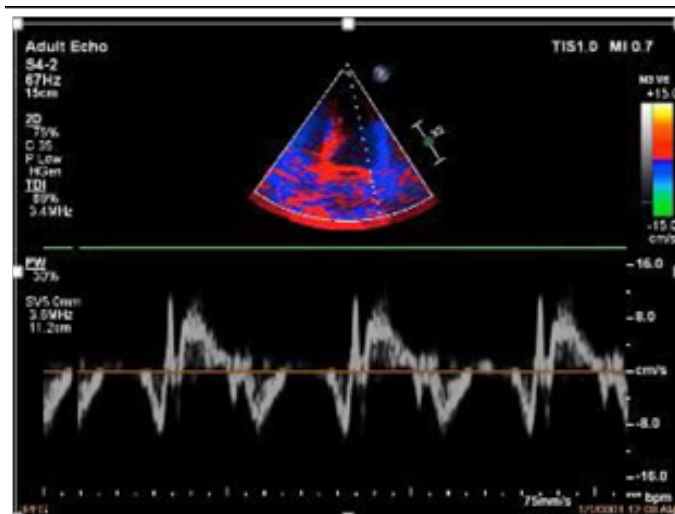


Figure 3.3: Tissue Doppler at the level of the lateral mitral ring; the diastolic function of the left ventricle can be evaluated.

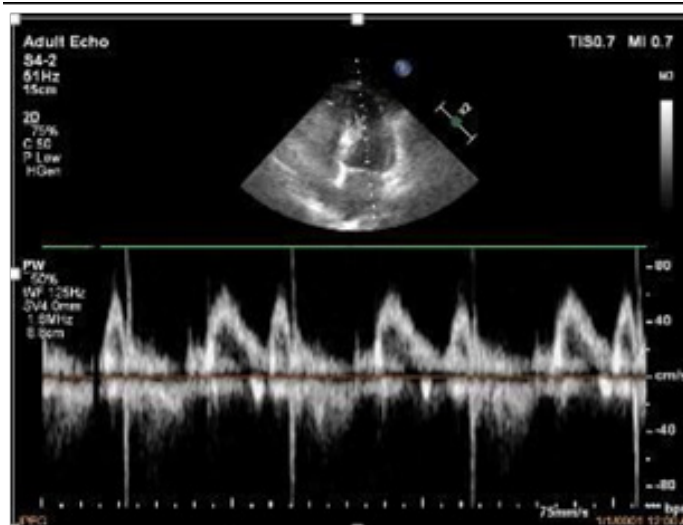
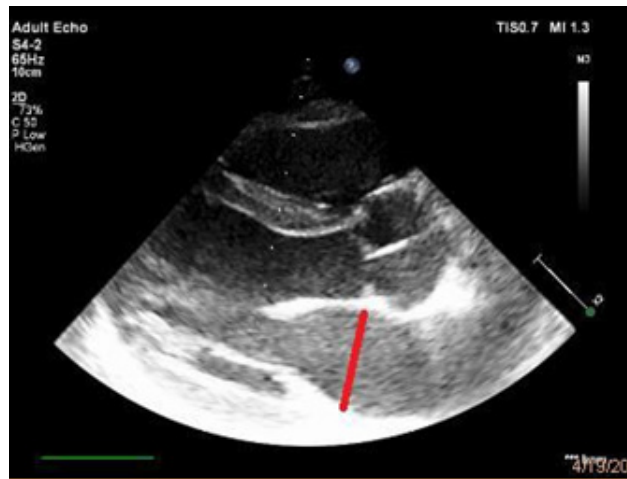
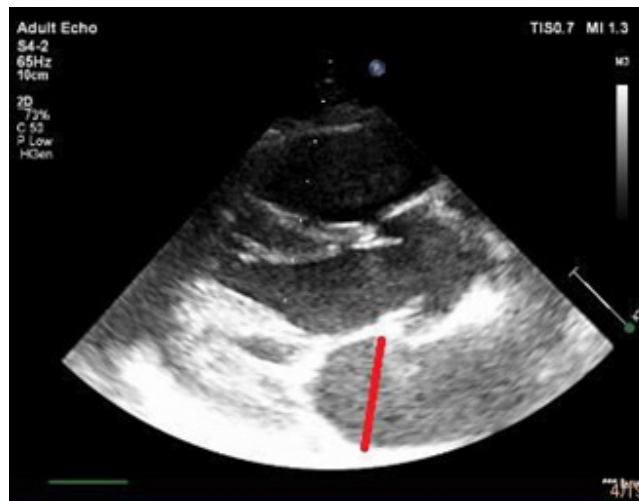


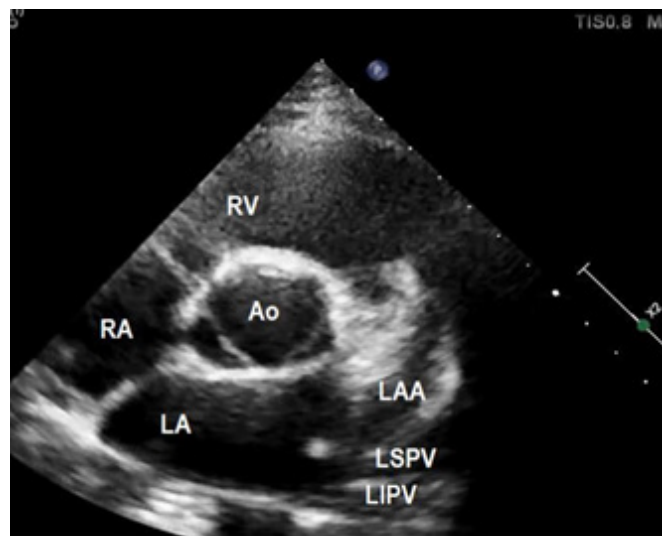
Figure 3.4: Transmitral doppler at the level of the lateral mitral ring; the diastolic dysfunction of the left ventricle can be evaluate.



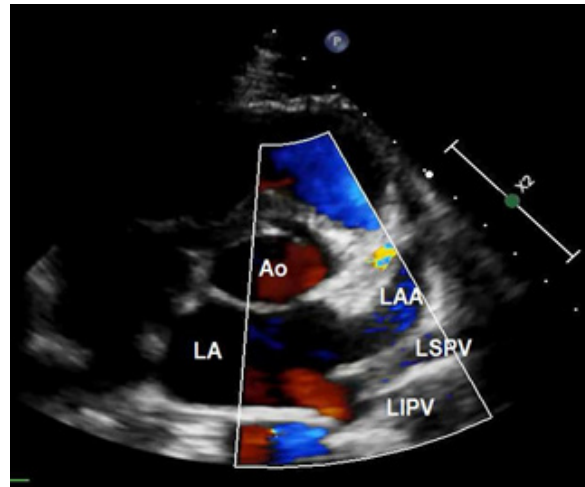
**Figure 3.5:** Bidimensional echocardiography from the long parasternal view. The left atrium is measured parallel with the mitral valve. The normal diameter is under 40mm. opened mitral valve.



**Figure 3.6:** Bidimensional echocardiography. The same patient as in figure. Left atrium is measured parallel with the mitral valve, but the measurement is made while the mitral valve is closed. The diameter of the left atrium is smaller than measured with the opened mitral valve.



**Figure 3.7:** Parasternal short axis view. On the lateral wall of the left atrium 3 structures can be seen: the most anterior is the left atrial appendage with a large ostium; in close proximity to the LAA drains LSPV which has an anterior to posterior direction; LIPV drains in the posterior region of LAA having a posterior to anterior direction.

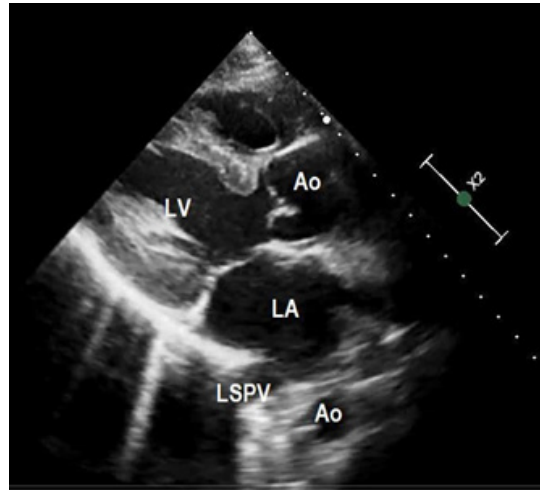


**Figure 3.8:** Parasternal short axis view. Color Doppler. On the lateral wall of the left atrium 3 structures can be seen: the most anterior is the left atrial appendage with a large ostium; in close proximity to the LAA drains LSPV which has an anterior to posterior direction; LIPV drains in the posterior region of LAA having a posterior to anterior direction.

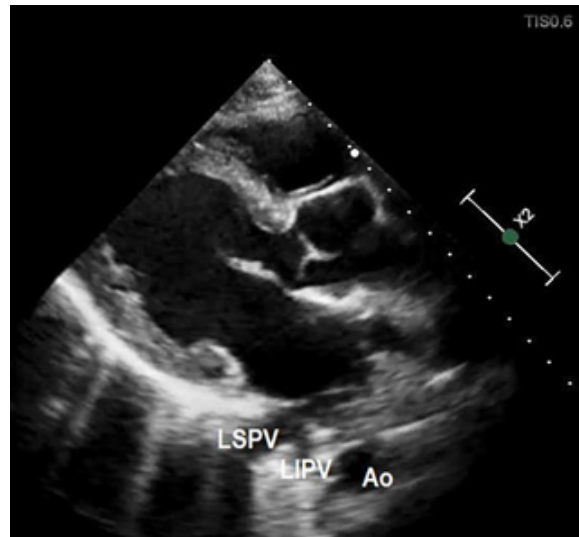
Three atrial volume can be measured: the maximum volume at end-systole, minimum volume and end-diastole and a pre-P volume before atrium contraction, we can then compute various phasic volumes: conduit volume=LV SV-LA SV; passive volume=Max L-Pre-p; active volume =Pre p LA-Min LA. All the 3 phasic volumes measurements have 4 disadvantages:

- a) There are geometric assumptions of biplane volume calculations.
- b) LA is a far-field structure and minor changes in the diameter will lead to important changes in the volume;
- c) There is a lack of normative data for volumetric indices and
- d) 3D echocardiography is superior in reducing the retest variability, but it is not routinely performed in clinical settings.

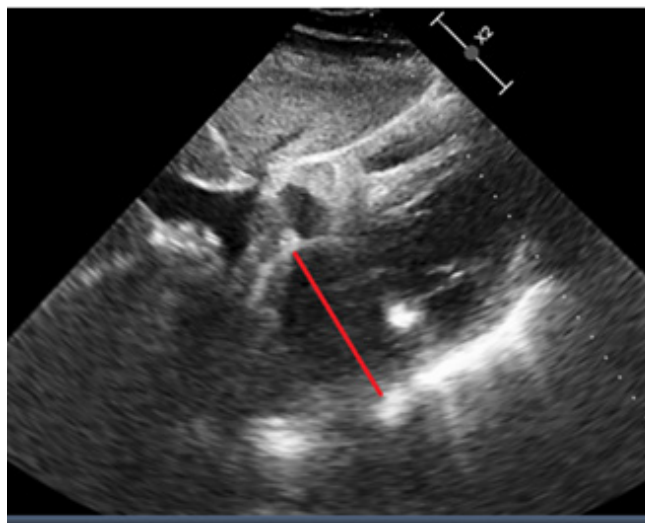
Pulmonary veins can be seen from the apical view and parasternal short axis view. LSPV takes oxygenated blood from the upper lobe of the left lung and from the lingula and brings it to the left atrium. The LIPV takes blood from the lower pulmonary left lobe and brings it to the left atrium. It enters the LA in a postero-inferior direction, almost perpendicularly on the posterior LA wall. It has an ostium which is more medial, and posterior compared to LSPV. RSPV takes oxygenated blood from the upper and middle lobe of the right lung and brings it to the LA. RIPV takes oxygenated blood from the lower left lobe and brings it to the LA. Compared to RSPV, RIPV has an ostium which is more medial and posterior. An experienced sonographer should adjust acoustic window for image optimization. RIPV is better seen from the apical four-chamber view, the vein drains almost perpendicular to the posterior wall of the left atrium. The RSPV is visible in near-five chamber view with the vein being in the postero-medial aspect of the LA. The RSPV is the easiest vein to identify as it has a flow that is parallel to the interatrial septum on the apical 4 chamber view. The most ideal view for LSPV is the short axis view, at the level of the aortic valve and LA where the vein could be seen entering the lateral LA in a left anterior to right posterior direction. LIPV can be seen in the same short axis view, entering the lateral LA in a left posterior to right anterior direction. From the subcostal view, RPSV and RIPV are visible. From the parasternal long axis view LSPV and LIPV are visible (Figure 3.9-3.21). To sum up, 2 D echocardiography is the most accessible imaging modality but consistently underestimates the left atrial volume compared with other imaging techniques. The choice of imaging modality used to assess left atrial volume should be tailored for a specific indication and clinical need of the patient and doctor.



**Figure 3.9:** Parasternal long axis view. The LSPV can be visualized entering the LA from a posterior region. There is a significant distance between the LSPV and descending aorta.



**Figure 3.10:** Parasternal long axis view. The LIPV is close to the LSPV and drain to the left atrium from a posterior position. LIPV is closer to the descending aorta compared to LSPV. LSPV=left superior pulmonary vein; LIPV= left inferior pulmonary vein; LA= left atrium; Ao = descending aorta



**Figure 3.11:** Bidimensional echocardiography. Subcostal view. Left atrium measured from the subcostal view.

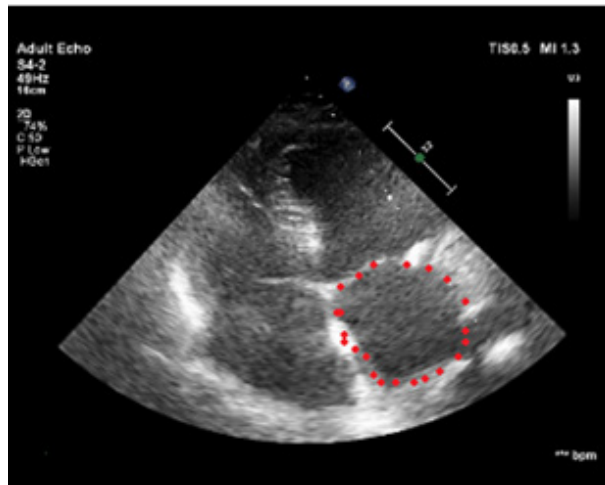


Figure 3.12: Bidimensional echocardiography. Apical view. Measurement of the left atrial surface.

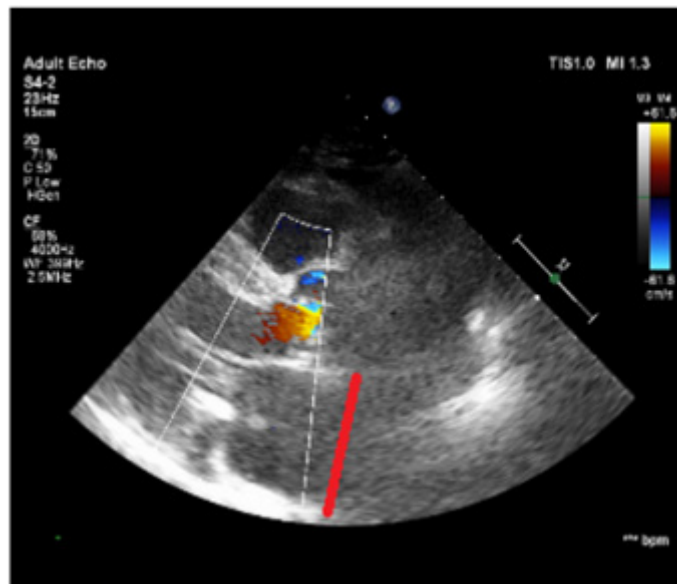


Figure 3.13: Bidimensional echocardiography. Parasternal long axis view. Left atrial diameter measurement.

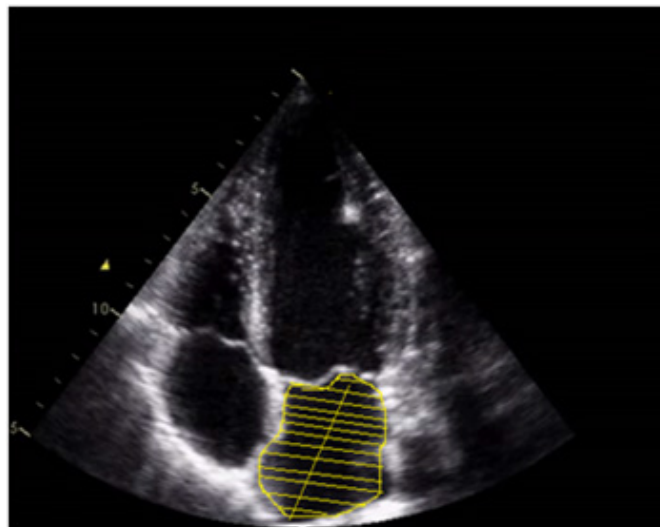
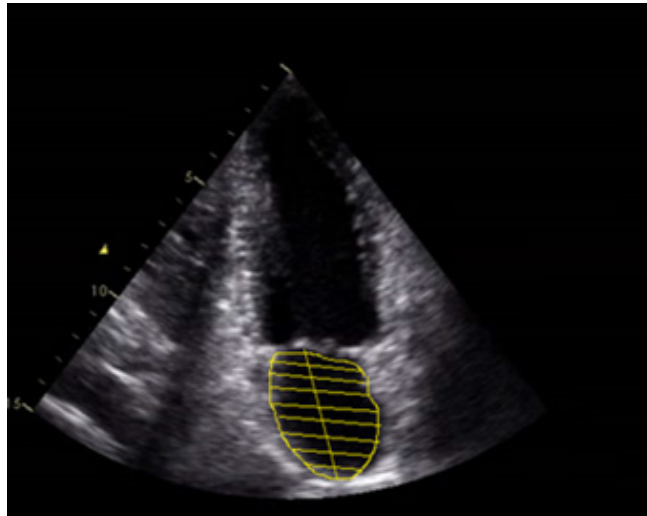
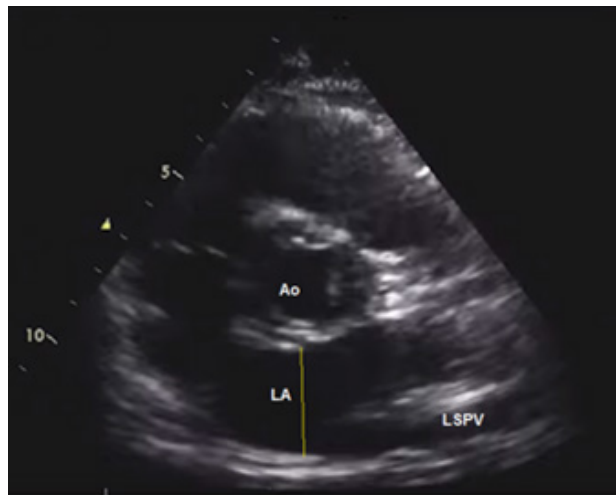


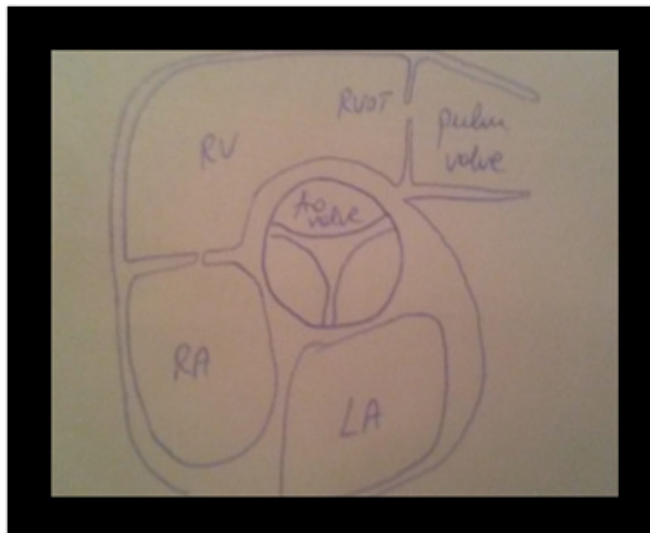
Figure 3.14: Bidimensional echocardiography. Apical view. Left atrial volume measurement using the biplane modified Simpson method. Four-chamber view.



**Figure 3.15:** Bidimensional echocardiography. Apical view. Left atrial volume measurement using the biplane modified Simpson method. Two-chamber view.

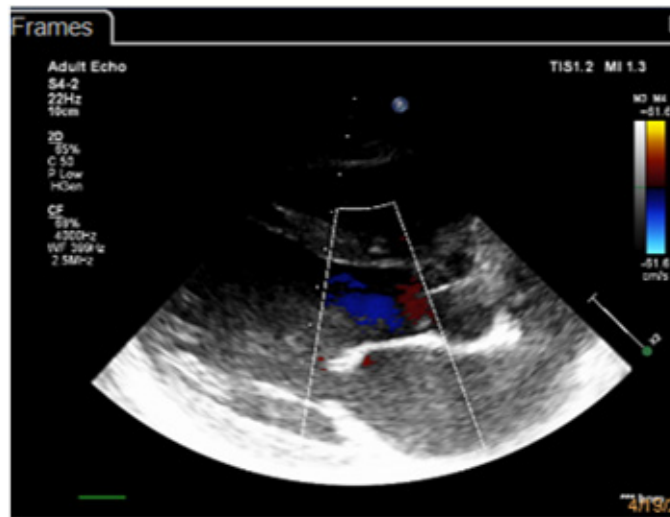


**Figure 3.16:** Bidimensional echocardiography. Parasternal short axis. Measurement of the diameter. Ao=aortic valve; LA=left atrium; LSPV=left superior pulmonary vein.

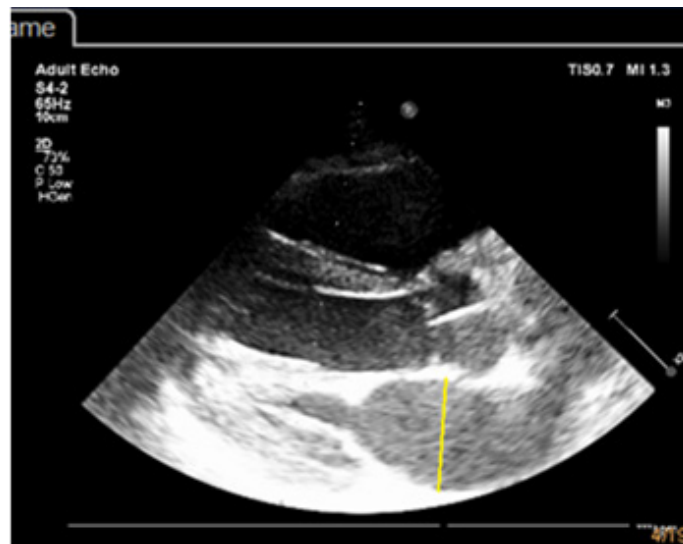


**Figure 3.17:** Bidimensional echocardiography. Parasternal short axis. AV=aortic valve; LA=left atrium; RA=right atrium, RV=right ventricle, RVOT=right ventricular outflow tract.

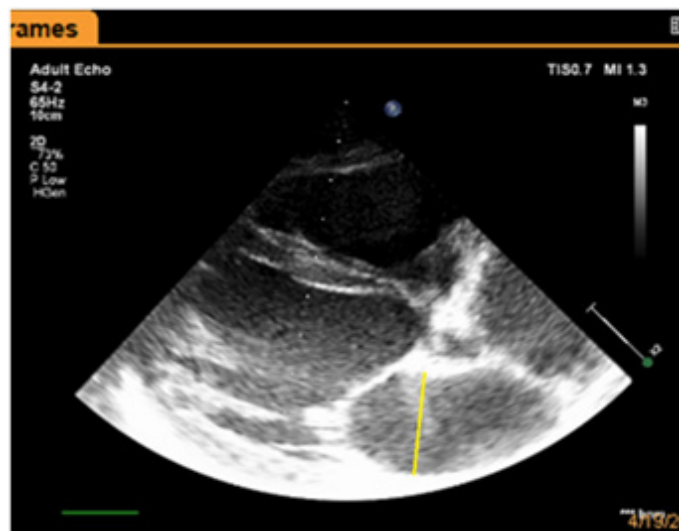




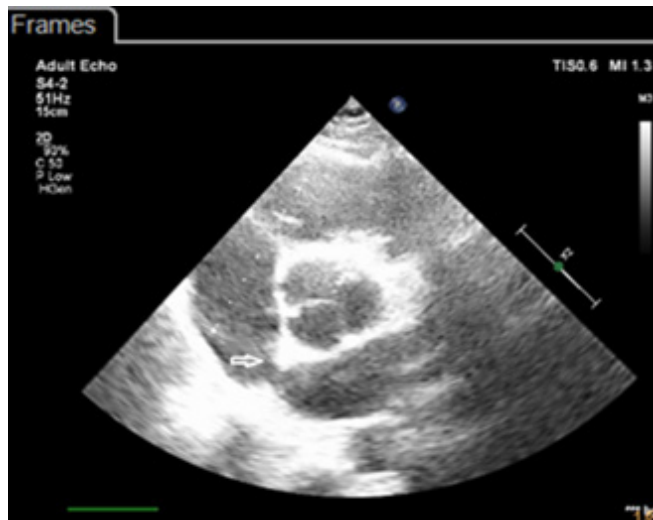
**Figure 3.18:** Bidimensional echocardiography. Parasternal long axis. There is no mitral regurgitation.



**Figure 3.19:** Bidimensional echocardiography. Parasternal long axis. Measurement of the LA diameter during atrial systole (opened mitral valve).



**Figure 3.20:** Bidimensional echocardiography. Parasternal long axis. Measurement of the LA diameter during atrial diastole (closed mitral valve).



**Figure 3.21:** Bidimensional echocardiography. Parasternal short axis view. The orifice between left atrium and right atrium is an artefact.



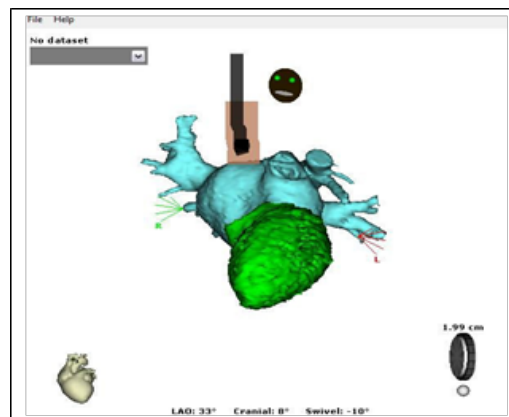
# Chapter 4

## Transesophageal Echographic Anatomy of the Left Atrium

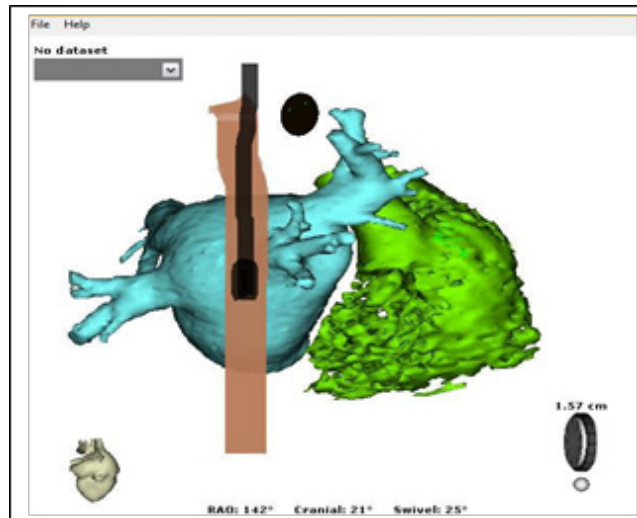
TEE uses sound waves that are sent and received by the transducer to create high-quality moving pictures of the heart chambers, blood and great vessels. The transducer is mounted on a flexible tube that can be introduced inside the esophagus and stomach. Therefore, more detailed pictures of the left atrium can be obtained as the esophagus lies directly behind the left atrium. Both 2 dimensional images and 3 dimensional images can be obtained but the standard are 2D images. For 3D, more details on the structure and function of the heart chambers and blood vessels can be obtained. Therefore, it is mostly used for patients with congenital heart disease, prosthetic valvopathies, and in the operating room to assist heart surgery.

In transesophageal echocardiography, the ultrasound probe is introduced inside the esophagus or stomach, mounted on a modified gastroscope in place of the fiberoptic. For TEE of the left atrium the patient should not eat 4-6 hours before the procedure, give a written consent, have an intravenous line for sedation if necessary, remove denture or mouth devices before giving a 2% lidocaine spray, should be monitored with a continuous ECG throughout the procedure and stay in a left lateral position. Routine antibiotic prophylaxis is not needed before TEE for LA and LAA. It is recommended only for high risk patients like those with a history of endocarditis or with prosthetic valves. After each TEE the probe should be disinfected and checked for any damage or electrical insulation problem.

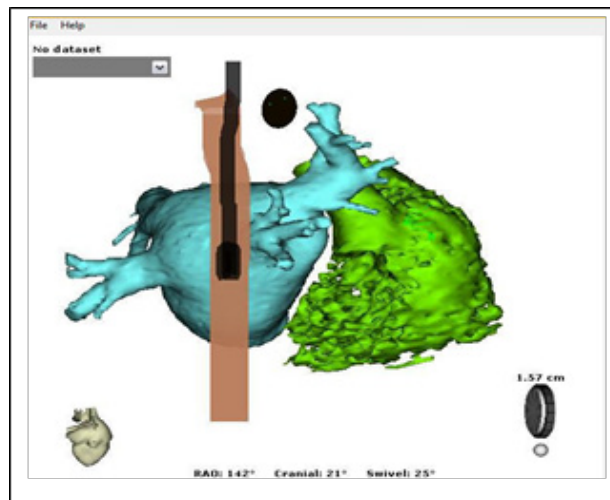
The monoplane TEE provides images in the horizontal plane and the multiplane TEE provides images rotated in an arc of 180°. The image quality is better than in transthoracic echocardiography because there is no lung or bone between the probe and the heart structures. From the esophagus, the first structure that is seen by the TEE probe is the left atrium, in contrast with intracardiac echocardiography (ICE) where the first cardiac structure is the right atrium (Figure 4.1-4.4). TEE is used especially before an electrical cardioversion of AF. IT provides a good view of the LAA and other parts of the LA [6] (Figure 4.5-4.7). As the esophagus has a variable position to the posterior wall of the left atrium, measurements of diameters and areas of the left atrium are not standardized with TEE. It remains the procedure of choice for left atrial is LAA thrombi assessment before a cardioversion [7]. Furthermore, emptying velocities of LAA are correlated with thrombus formation ( $v < 20 \text{ cm/s}$ ) and with persistence of sinus rhythm after a successful cardioversion ( $v > 40 \text{ cm/s}$ ) (Figure 4.8-4.29). Some centers perform transseptal puncture for AF ablation under TEE guidance. The best views for quantification of the left atrium are:



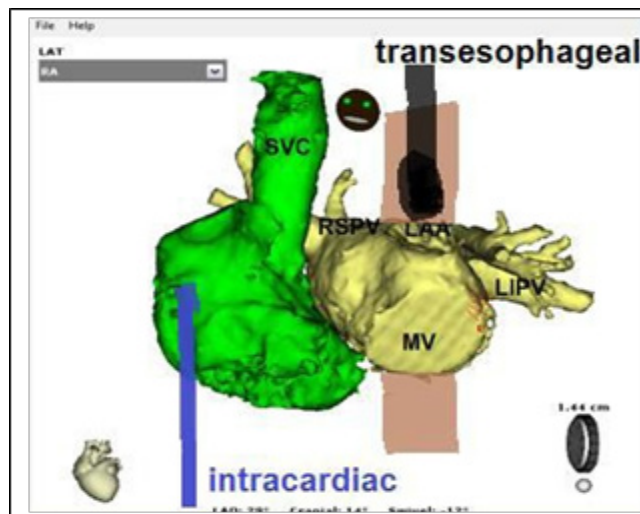
**Figure 4.1:** In transesophageal echocardiography the probe is inserted posterior to the left atrium at the level of esophagus.



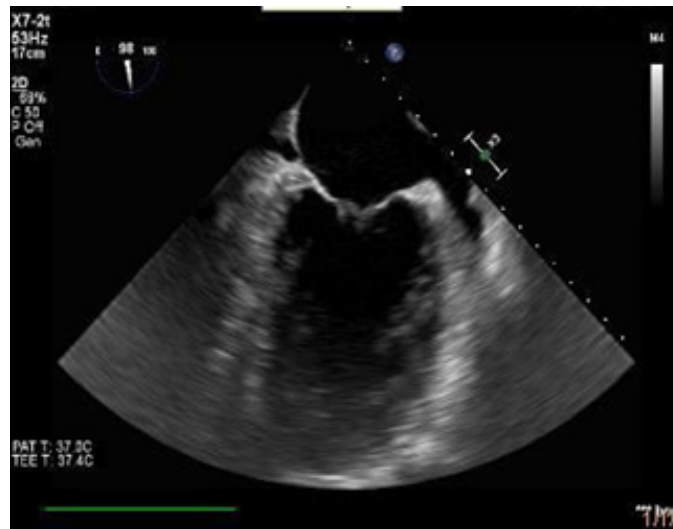**Figure 4.2:** The probe is inserted at the midesophageal level. In order to see the right atrium, it should be oriented to the right.



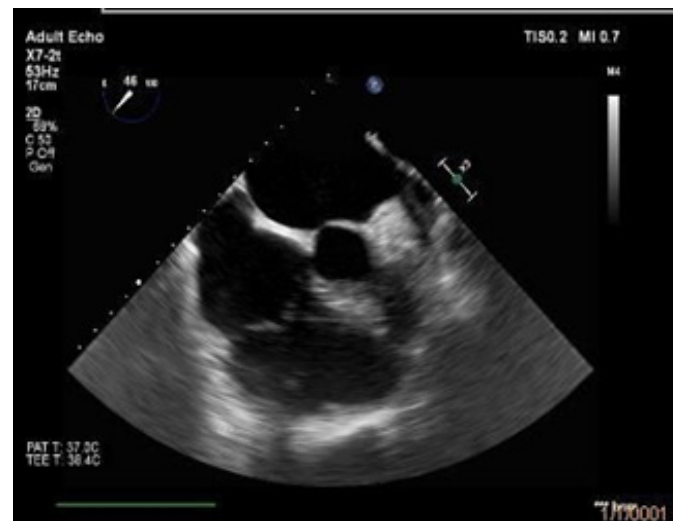**Figure 4.3:** The probe is inserted at the midesophageal level. In order to see the right atrium, it should be oriented to the right.



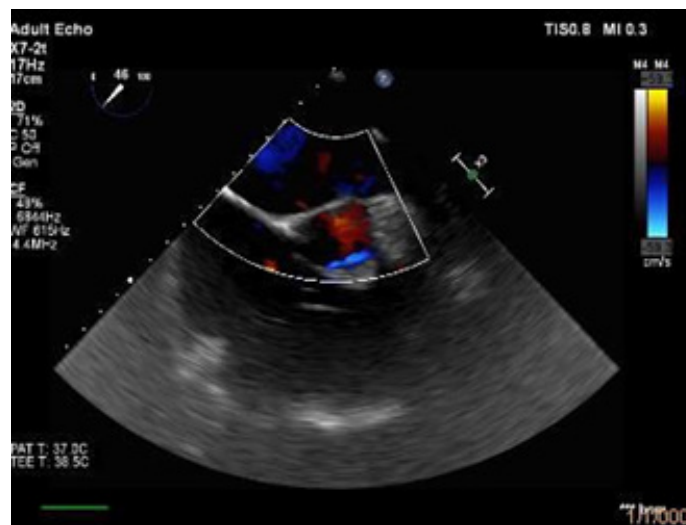
**Figure 4.4:** Compared to intracardiac echo, where the heart structures are seen from the middle of the right atrium, in transesophageal echocardiography, cardiac structures are seen from behind the left atrium.



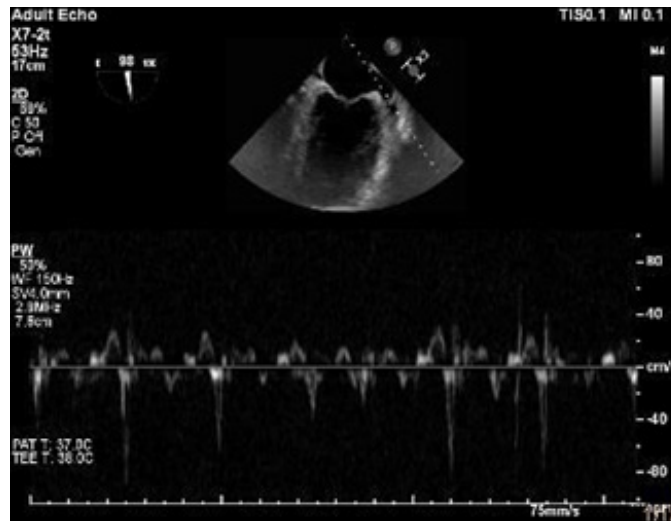
**Figure 4.5:** Transesophageal echocardiography. Midesophageal view at 98°. The left atrial appendage is close to the mitral ring. There is no thrombus at this level.



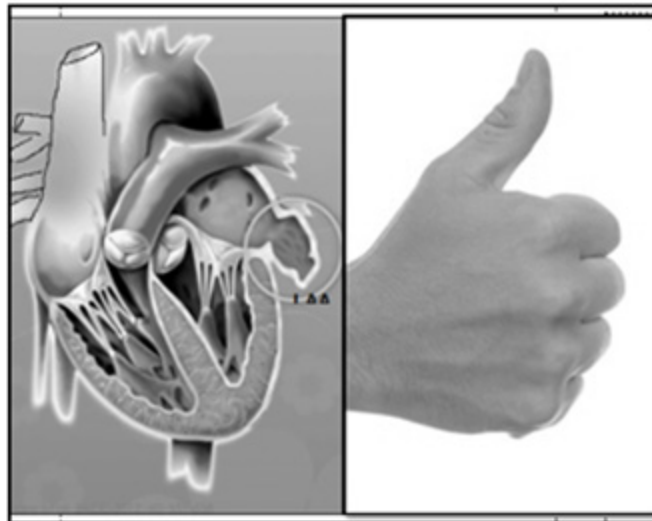
**Figure 4.6:** Transesophageal echocardiography. Midesophageal view at 46°. The left atrial appendage has no thrombus.



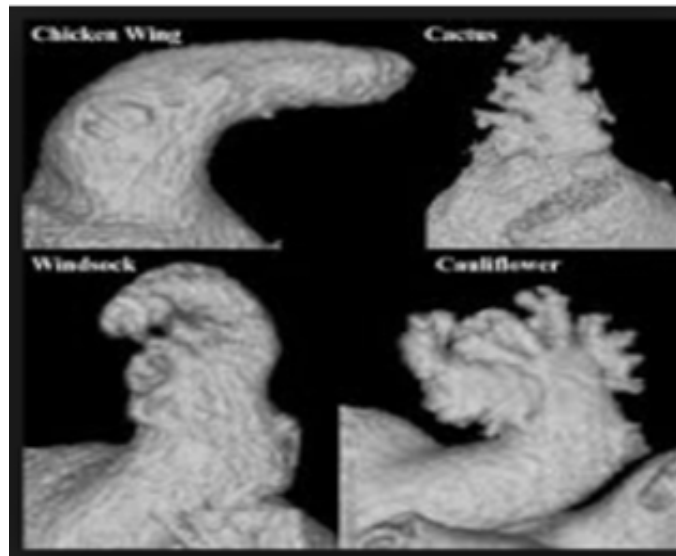
**Figure 4.7:** Transesophageal echocardiography. Midesophageal view at 46°. The left atrial appendage has no thrombus which can be also demonstrated by color Doppler.



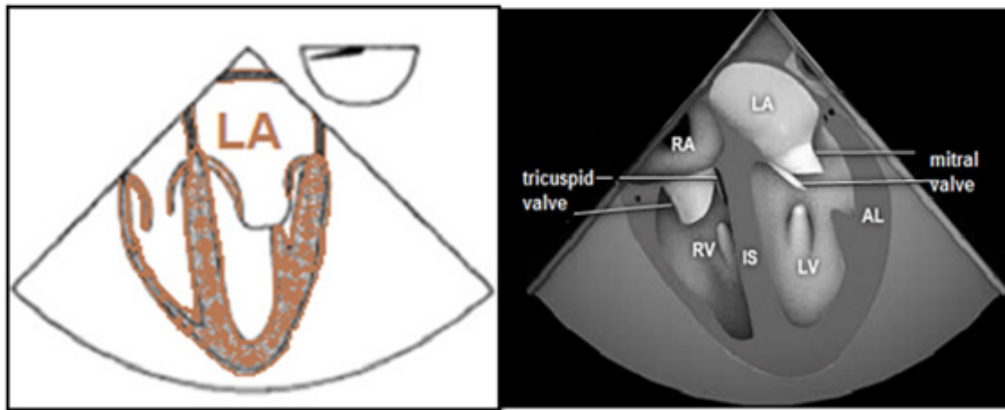
**Figure 4.8:** Transesophageal echocardiography. Midesophageal view at 98° with pulsed Doppler. The velocity inside the LAA is > 80cm/s.



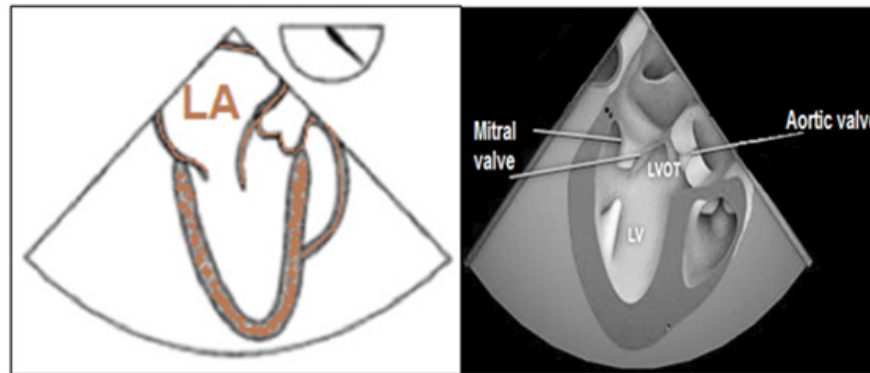
**Figure 4.9:** The left atrial appendage has a finger-shape appearance.



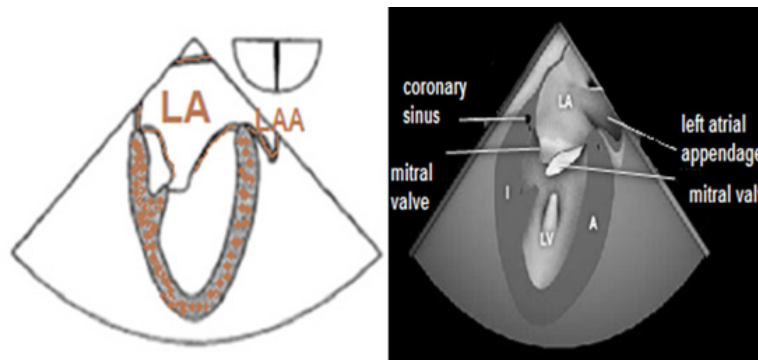
**Figure 4.10:** Types of left atrial appendage in function of the morphology: chicken wing, cactus, windsock, cauliflower [12].



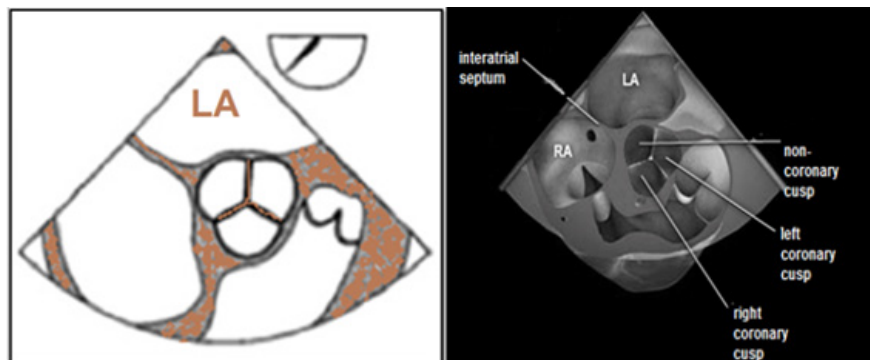
**Figure 4.11:** Schematic drawing. Midesophageal four-chamber view. The left atrium is visible in the superior part of the screen.



**Figure 4.12:** Schematic drawing. Midesophageal long axis view. The left atrium is visible in the superior part of the screen as the probe is inserted inside the esophagus.

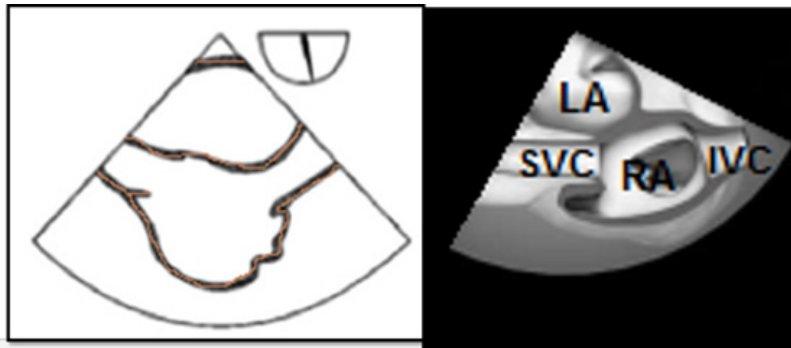

**Figure 4.13:** Schematic drawing. Midesophageal two-chamber view. The left atrium and the left atrial appendage are visible.

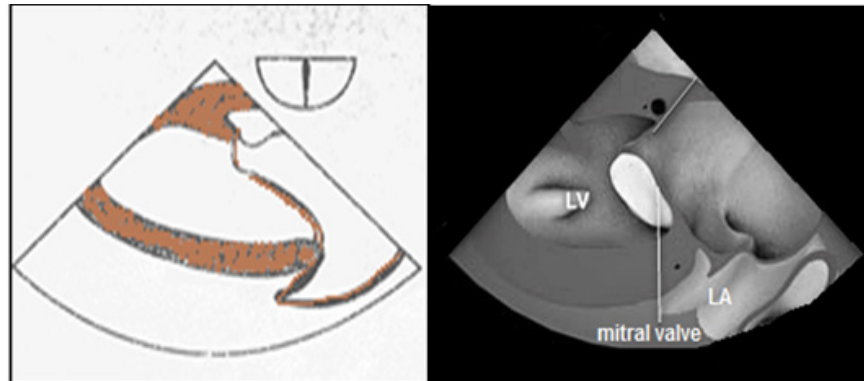


**Figure 4.14:** Schematic drawing. Midesophageal, aortic valve short axis view. The left atrium is in the superior part of the screen, posterior to the aortic valve.

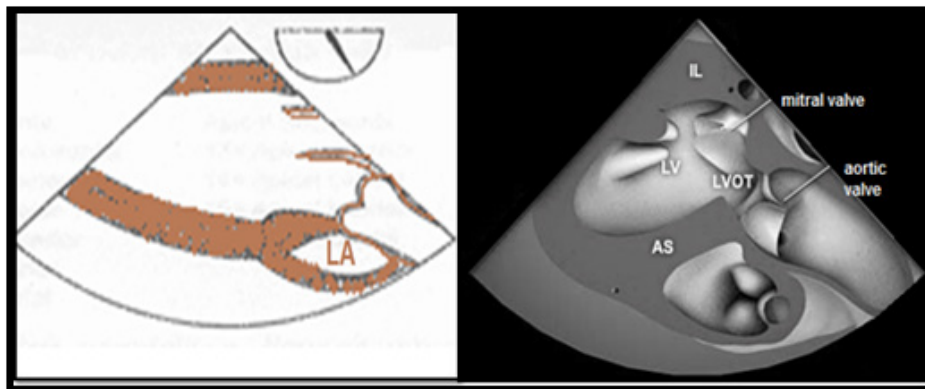




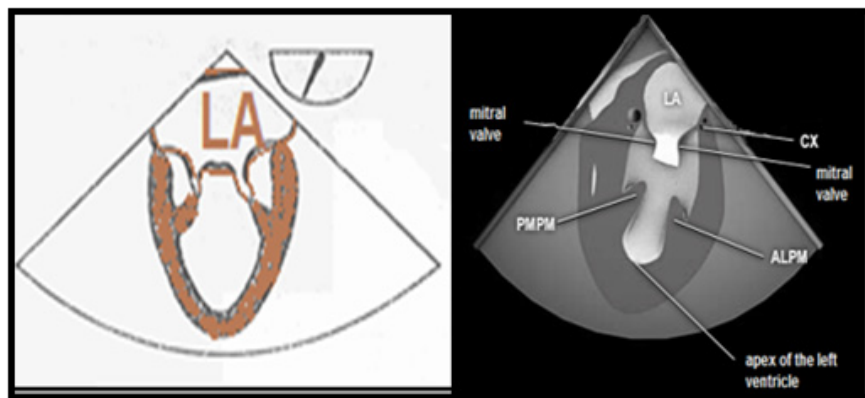
**Figure 4.15:** Schematic drawing. Midesophageal bicaval view. The left atrium is in the superior part of the image, separated from the right atrium by the interatrial septum.



**Figure 4.16:** Schematic drawing. Transgastric two-chamber view. The left atrium is in the right part of the image.

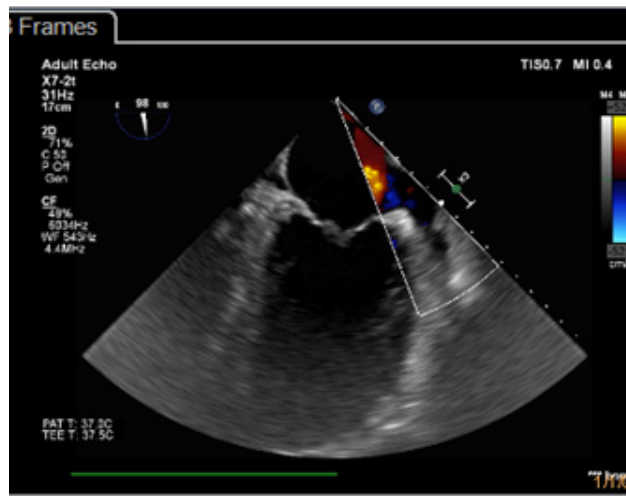


**Figure 4.17:** Schematic drawing. Transgastric long axis view. The left atrium is in the inferior part of the image.

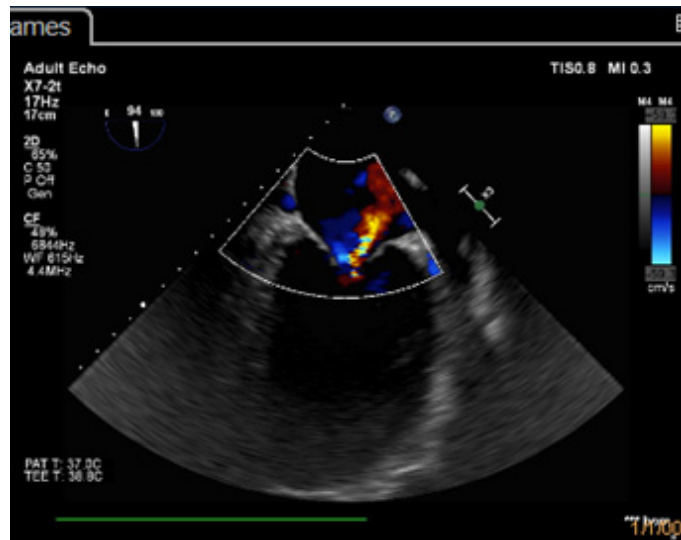


**Figure 4.18:** Schematic drawing. Transesophageal echocardiography. The mitral valve is in the middle of the image, with the anterior and posterior papillary muscles visualized.

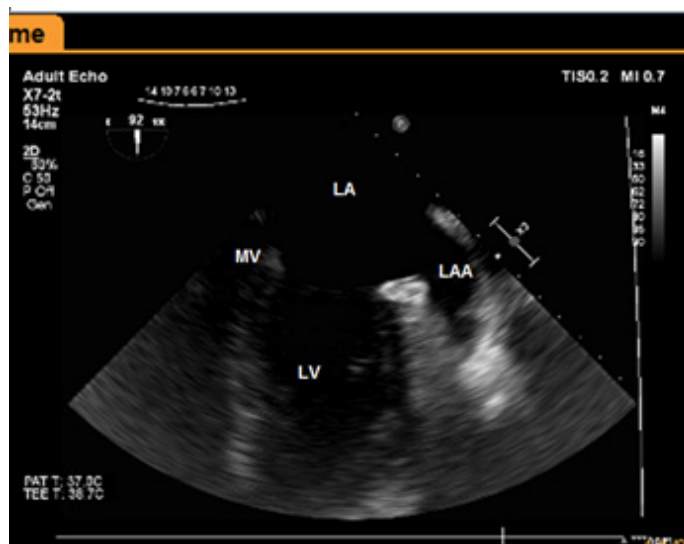




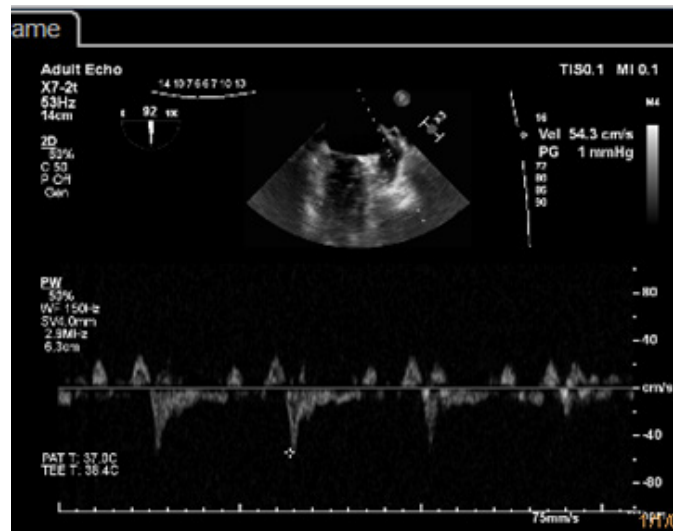
**Figure 4.19:** Transesophageal echocardiography. Midesophageal view at 90 degrees. Color Doppler- no thrombus inside the left atrial appendage.



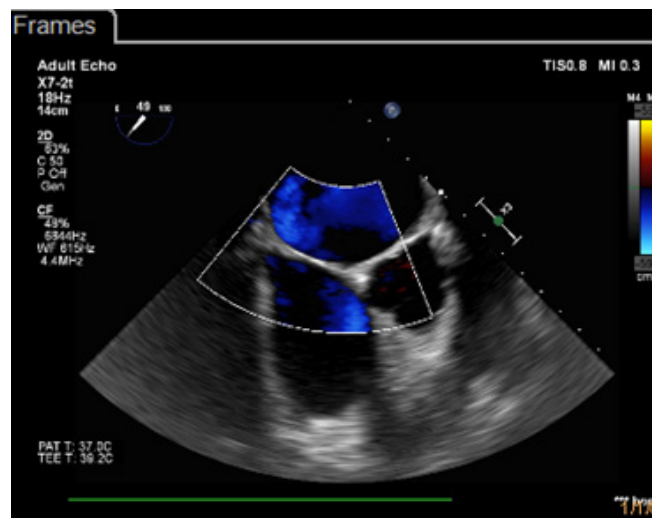
**Figure 4.20:** Transesophageal echocardiography. Midesophageal view at 90 degrees. Color Doppler shows mitral regurgitation in a patient with moderate dilation of left atrium.



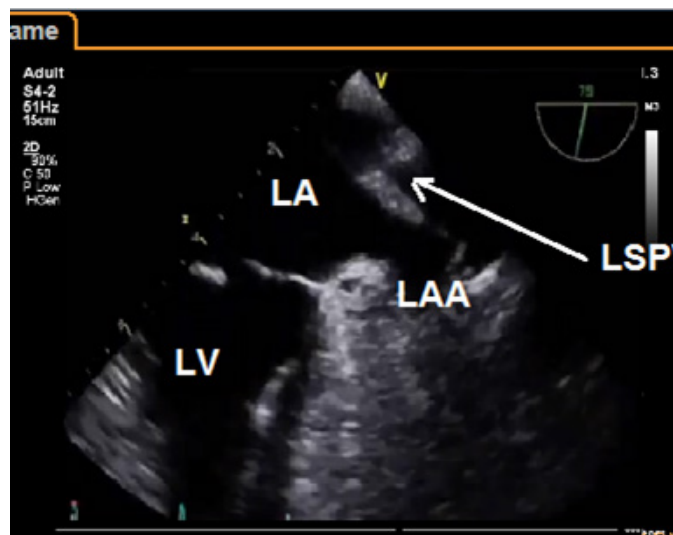
**Figure 4.21:** Transesophageal echocardiography. Midesophageal view at 92 degrees. Left atrial appendage without any thrombus.



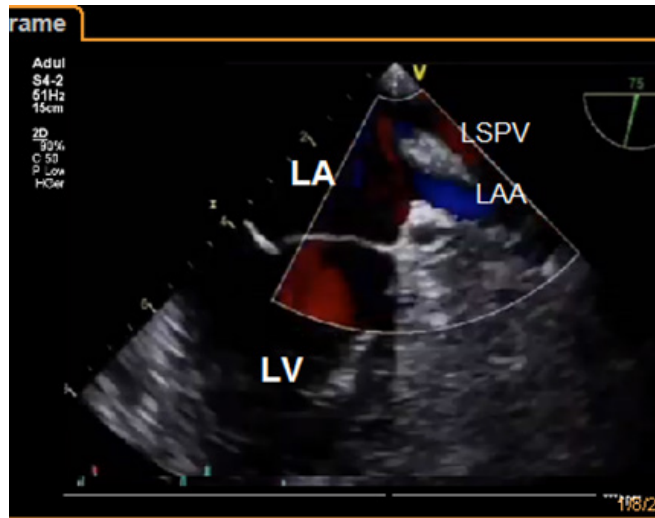
**Figure 4.22:** Transesophageal echocardiography. Midesophageal view at 90 degrees. Pulsed Doppler flow during sinus rhythm shows an emptying velocity of > 40cm/s.



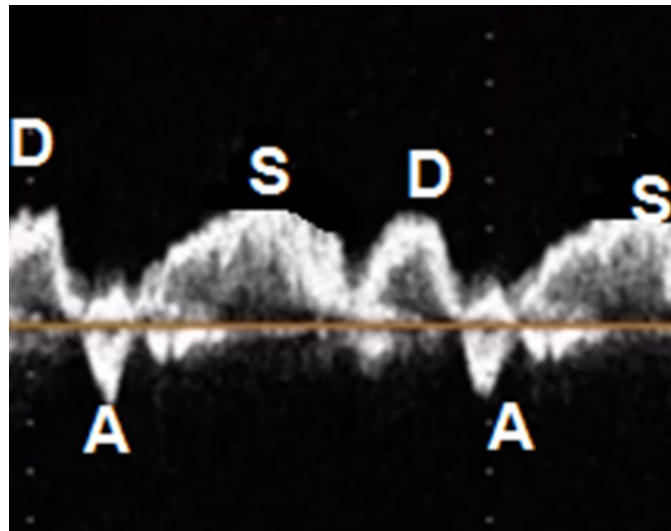
**Figure 4.23:** Transesophageal echocardiography. Midesophageal view at 49 degrees. Interatrial septum without any PFO.



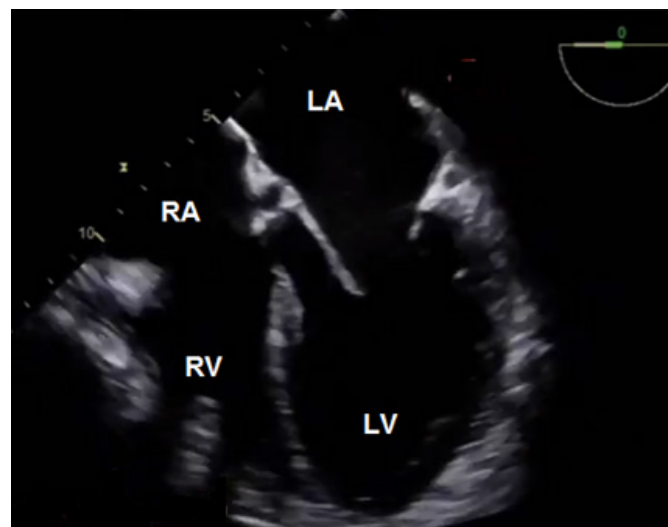
**Figure 4.24:** Transesophageal echocardiography. Midesophageal view at 75 degrees. Between the LAA and LSPV the ridge is present, which is an important structure for catheter ablation of atrial fibrillation because in order to isolate the LSPV, multiple RF applications should be done at this level.



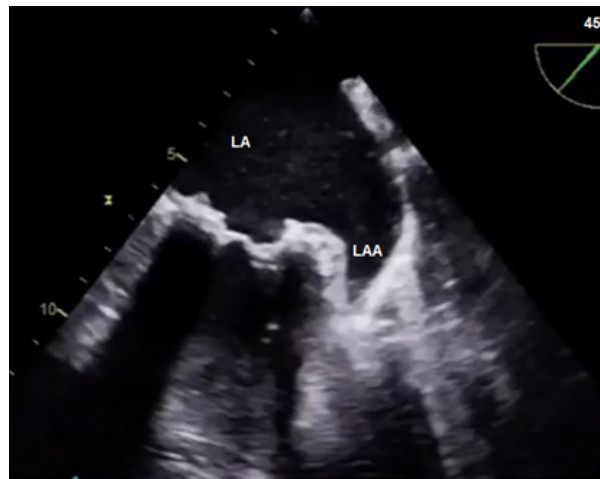
**Figure 4.25:** Transesophageal echocardiography. Midesophageal view at 75 degrees. Color Doppler shows red color inside LSPV.



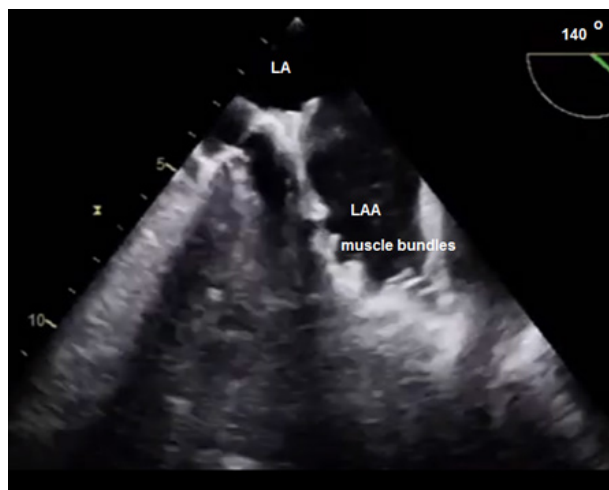
**Figure 4.26:** Transesophageal echocardiography. Midesophageal view at 75 degrees. Pulsed Doppler at the level of LSPV shows the presence of 3 waves: S, D and A.



**Figure 4.27:** Transesophageal echocardiography. Midesophageal view at 0 degrees. All 4 chambers are visible.



**Figure 4.28:** Transesophageal echocardiography. Midesophageal view at 45 degrees. Left atrial appendage is visible.



**Figure 4.29:** Transesophageal echocardiography. Midesophageal view at 140 degrees. Left atrial appendage is visible with prominent muscle bundles.

- a) Midesophageal 4 chamber view at 0°,
- b) Midesophageal 2 chamber view at 90°,
- c) Midesophageal long axis view at 120°,
- d) Midesophageal aortic valve view at 3-45°,
- e) Midesophageal right ventricular inflow and outflow view at 60-75°,
- f) Midesophageal bicaval view at 90°,
- g) Midesophageal commissural view at 60°,
- h) Midesophageal aortic valve view long axis 120°,
- i) Transgastric 2 chamber view at 90° and
- j) Transgastric long axis view at 110-120°.

TEE has the advantage of a short distance between the transducer and the left atrium: 2-3mm, it is close to posterior structures such as LSPV, LIPV, RSPV, RIPV, LA, LAA and descendant aorta, it is far from surgical area and can be used for intra-operative monitoring and permits a high resolution imaging due to absence of lung or bone between the transducer and the heart.

Disadvantages of TEE are the following: it needs a special setup, technique, preparation and instrumentation, it needs expertise and it is a semi invasive procedure with chances of injury of the mouth, teeth, pharynx, esophagus and stomach. Therefore, it is not used in patients with stricture or obstruction of the esophagus, gastrointestinal bleeding that was not evaluated or instability of cervical vertebrae. For patients with esophageal varices or diverticula, cervical arthritis, oropharyngeal distortion, or over coagulation, TEE can be used, but with caution, because the mentioned are relative contraindications to TEE.

For pulmonary vein visualization transesophageal echocardiography has a better resolution for the superior veins with almost 100% success rate for identification compared to inferior vein where is 95% [8]. RSPV can be found behind the superior vena cava while LSPV and LIPV are localized between the LAA and descending aorta.

All 4 veins can be visualized using the midesophageal position of the transducer. In the midesophageal 4 chamber view RSPV can be visualized by turning the probe to the right. The vein enters the left atrium from a superior position. The image is better seen at an angle of 30°. RIPV can also be seen in the midesophageal view with the probe turned to the right; the vein enters inside the left atrium from an infero-posterior position which can be seen also by rotating the probe at 30°. In the midesophageal bicaval view RSPV and RIPV can be visualized by turning the probe to the left and using a rotation angle of 90°. In the midesophageal 2 chambers view, by turning the probe to the left with a rotation of 60° the LSPV can be visualized entering the LA. LSPV will be seen between the aorta and LAA. By rotating the probe to 100°, both LSPV and LIPV can be seen in the vertical plane.

Complications that can appear during LA or LAA evaluation by TEE are: death or laryngospasm, esophageal rupture, sustained VT or aggravation of heart failure are major complications, occurs rarely in about 0.3 % of the patients. Minor complications such as: supraventricular tachycardia, atrial fibrillation, ventricular tachycardia, bradycardia, transient hypotension or hypertension, angina and pulmonary edema occur more frequently than major complications, but they remain at a low rate.

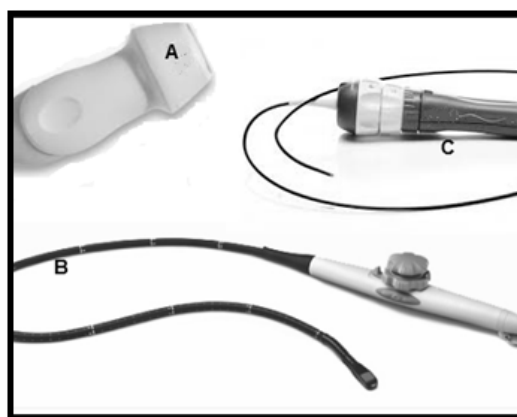
# Chapter 5

## Intracardiac Echographic Anatomy of the Left Atrium

Intracardiac echocardiography is an imaging technique that helps to guide interventional procedures. The probe can be inserted through an inferior or superior vein under local anesthesia. It is principally used for catheter ablation of atrial fibrillation, transeptal puncture guiding, closure of the left atrial appendage, closure of atrial septal defects and mitral clip.

The first generation of ICE was introduced in 1980s as it provides a high-resolution imaging and was used to visualize structures that were not visible because of lung or bone interfering with the ultrasound. Recently, the development of steerable phased array ultrasound catheters using low frequency and doppler (pulsed, color, continuous) had expanded the use of ICE.

Compared to transthoracic and transesophageal probes, the intracardiac probe is smaller and mounted on an intracardiac catheter. Phased array ICE permits only monoplane image sections. There are no standard views like in TEE or TTE as it is difficult for operators to obtain the same views. Compared to mechanical ultrasound tipped catheter which uses only 8F introducers, in phased array ultrasound tipped catheter a 10F introducer is needed. Phased array ICE can be performed using the Acunav Ultrasound Catheter or Viewflex Xtra Catheter and mechanical ICE can be performed with the Ultra ICE Plus catheter (Figure 5.1-5.4). The first 2 have phased-array transducers and the third has a rotational transducer. ICE is used especially during AF catheter ablation procedure and closure of atrial septal defects. Like in TEE, no standardized measurements are available for the diameter, area or volume. At the beginning and the end of the procedure, mechanical ultrasound tipped catheters can be used both for intracardiac and intravascular imaging: from a vein or an artery. For intracardiac ultrasound a 9MHz single element transducer is incorporated in an 8F catheter and a piezoelectric crystal is rotated at 1800 rotations per minute in the radial dimension to obtain a perpendicular section to the catheter plane. Therefore, it provides a cross sectional image in a 360 degrees radial plane. Furthermore, the ICE catheter needs to be filled with 3-5ml of sterile water before it is connected to the ultrasound machine. In contrast to mechanical transducers, phased array ultrasound tipped catheter system uses a 10F catheter, positioned in the right atrium, right ventricle, RVOT or even in the aorta, via a femoral or jugular approach, through a 10F introducer. The catheter is connected to an ultrasound machine that permits hemodynamic measurements using Doppler imaging.



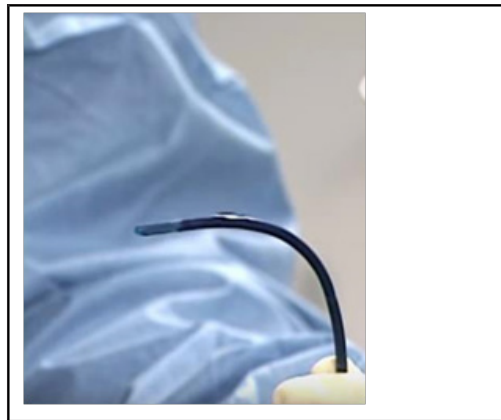
**Figure 5.1:** The intracardiac probe compared to transthoracic and transesophageal probes.

- A. Transthoracic sectorial probe.
- B. Transesophageal multiplanar probe.
- C. Intracardiac sectorial probe.

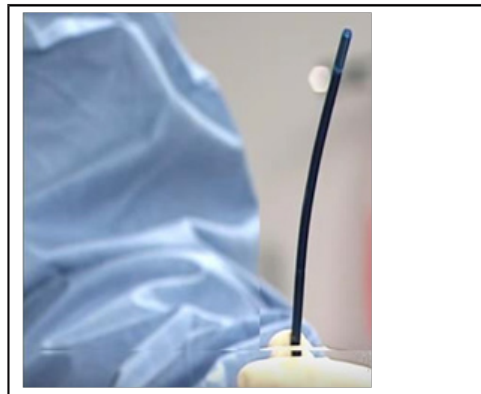




**Figure 5.2:** View Mate echo machine used for intracardiac echocardiography. The View Mate ultrasound console has several imaging modes: 2-dimensional, pulsed wave, color Doppler, tissue Doppler imaging and continuous wave.



**Figure 5.3:** The Xtra ViewFlex catheter can be bended in the anterior-posterior direction. It is inserted through the femoral vein to the middle of right atrium.

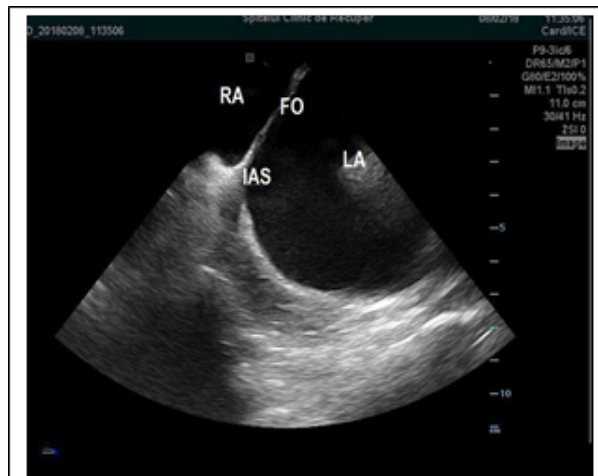


**Figure 5.4:** The Xtra View Flex catheter can also be bended in the left-right direction. It is inserted through the femoral vein to the middle of right atrium.

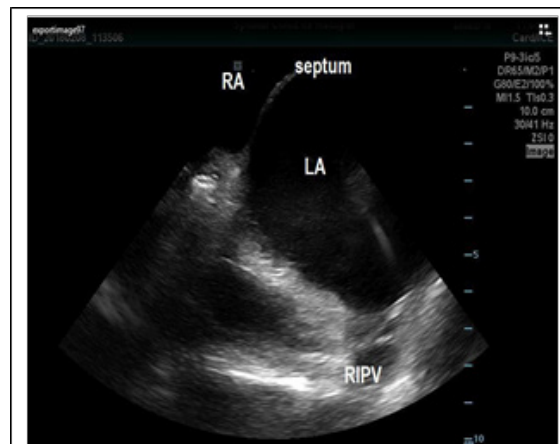
ICE confirms the absence or presence of pericardial fluid which can be a complication of the ablation itself. When ICE is associated with doppler capacities it can confirm the presence of a pulmonary vein stenosis, another complication of AF ablation. ICE can be used for interventional procedures to assess: the presence of a cardiac thrombus, to assist transseptal puncture, to facilitate atrial septal defect closure or patent foramen ovale closure, and to guide electrophysiological procedures: pulmonary vein isolation during catheter ablation of atrial fibrillation, cavo-tricuspid isthmus ablation for atrial flutter or papillary muscle ablation for ventricular tachycardia. Other new indications for ICE are: precision diagnosis of cardiac masses with or without biopsy, balloon mitral valvuloplasty, atrial appendage closure and visualization

of the coronary sinus for cardiac resynchronization therapy. During AF ablation, ICE provides online information on the position of the ablation catheter and relationship with the antrum of the pulmonary vein. The posterior, anterior, superior and inferior walls of the pulmonary vein can be assessed. Two types of bubbles can be seen during catheter ablation [9]: scattered microbubbles sign of tissue overheating and dense microbubbles sign of high impedance.

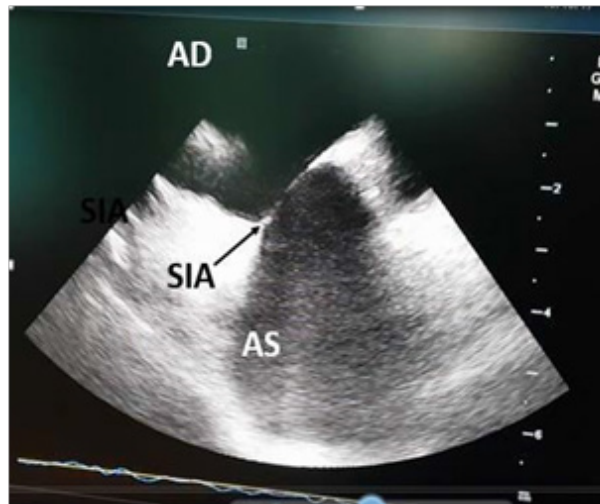
The use of ICE starts with the introduction of the probe inside the right atrium. The right ventricle is first visualized to exclude a pericardial effusion at the starts with of the procedure. Than the left atrium is scanned with the four pulmonary veins, searching for anomalies of the veins. For the transseptal puncture the interatrial septum with the fossa ovalis is visualized along with the left pulmonary veins to assure a puncture without complications. After tenting the fossa ovalis the needle is advanced from the right atrium to the left atrium and the serum injected for confirmation. The transseptal sheath is than advanced inside the let atrium. Through the transseptal sheath a guidewire is advanced to the left superior pulmonary vein. Using the same septal orifice or after another transseptal puncture a Lasso catheter is inserted inside the left atrium. With the use of the Lasso catheter pulmonary veins are scanned for identification of pulmonary vein potentials. Catheter ablation is performed at the antrum of the vein in order to avoid pulmonary vein stenosis (Figure 5.5-5.60).



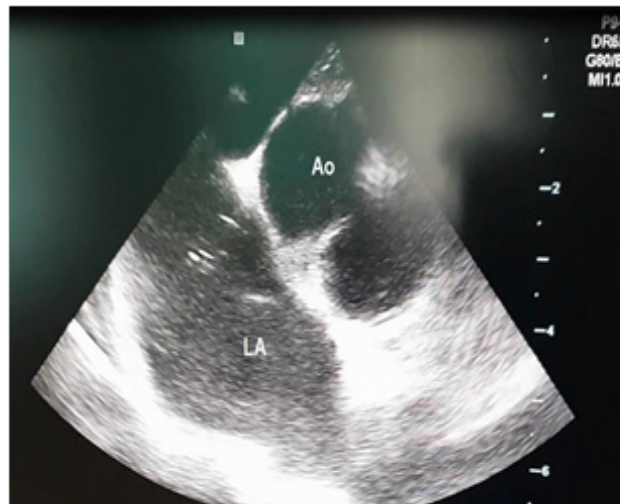
**Figure 5.5:** Intracardiac echocardiography during catheter ablation of atrial fibrillation. Transseptal puncture should be performed at the level of fossa ovalis. Fossa ovalis is the thinnest part of the interatrial septum. A puncture pointed to the muscular part of interatrial septum is dangerous as it may complicate with cardiac tamponade due to small vessel destruction in this part of the septum.



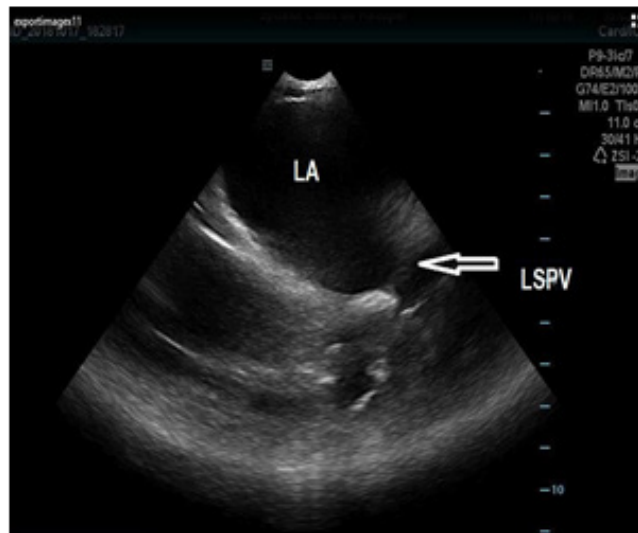
**Figure 5.6:** Intracardiac echocardiography with the probe inserted in the middle of the right atrium. Right inferior pulmonary vein can be visualized. RA=right atrium; septum=interatrial septum; LA=left atrium; RIPV=right inferior pulmonary vein.



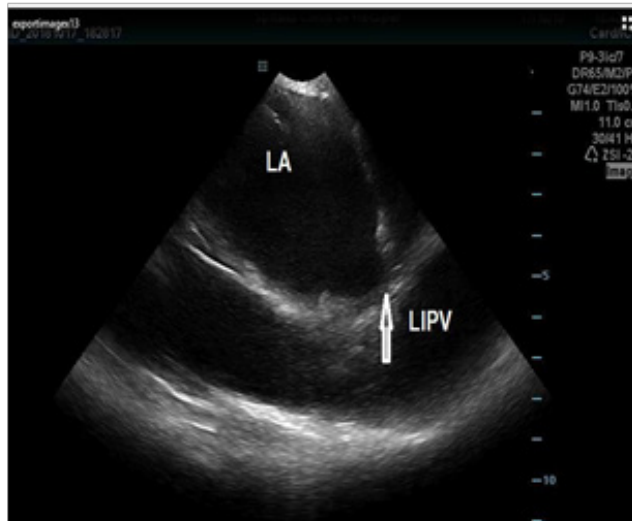
**Figure 5.7:** Intracardiac echocardiography during pulmonary vein isolation. The interatrial septum lies between the left atrium and the right atrium. Fossa ovalis is the thinnest part of the septum. Transseptal puncture should be performed at the level of fossa ovalis.



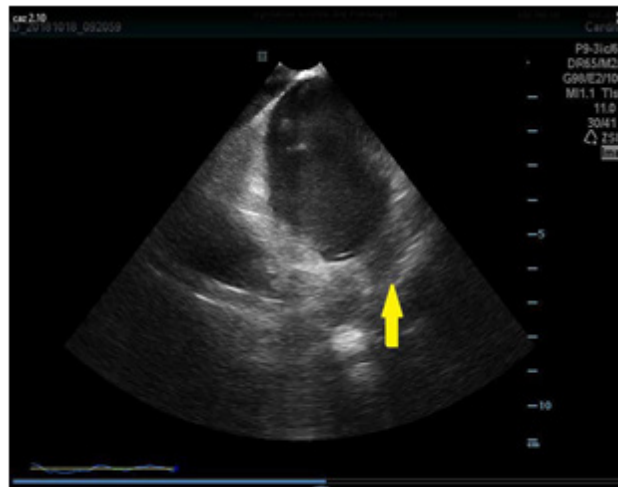
**Figure 5.8:** Intracardiac echocardiography during pulmonary vein isolation. In this image the left atrium and the aorta can be seen. When transseptal puncture is made anteriorly there is a risk of perforating the aortic wall.



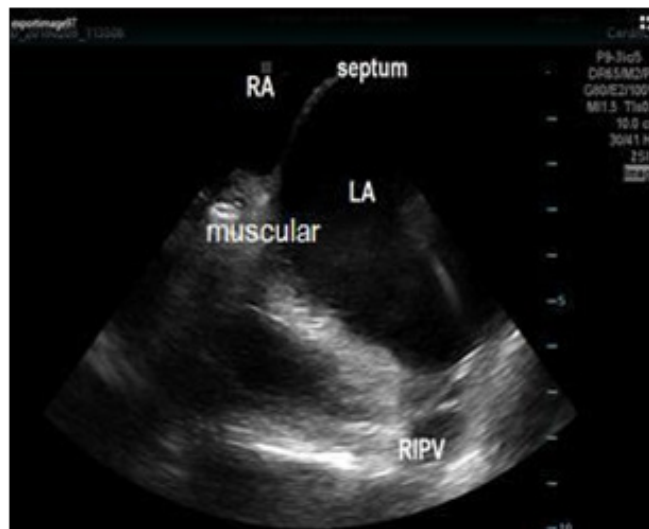
**Figure 5.9:** Intracardiac echocardiography with the probe inserted in the middle of the right atrium. For transseptal puncture is necessary to have interatrial septum and LSPV or LIPV in the same plane.



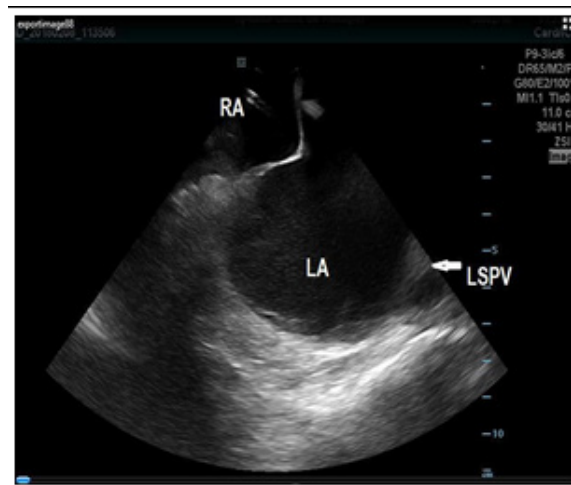
**Figure 5.10:** Intracardiac echocardiography with the probe inserted in the middle of the right atrium. For transseptal puncture is necessary to have interatrial septum and LSPV in the same plane.



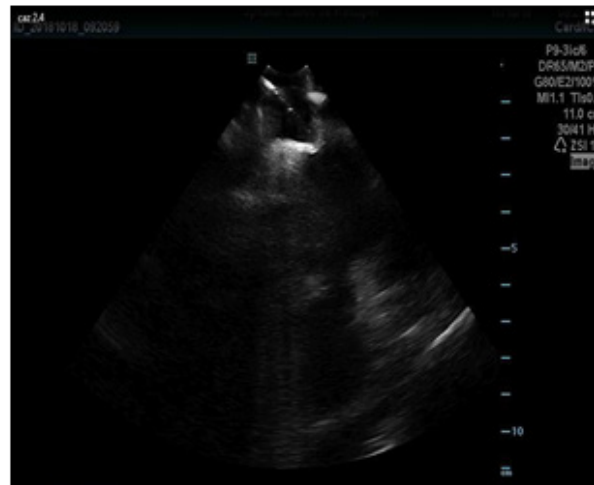
**Figure 5.11:** Intracardiac echocardiography. In this view the interatrial septum can be seen in the same plane with the left inferior vein. This is a safe plane for transseptal puncture.



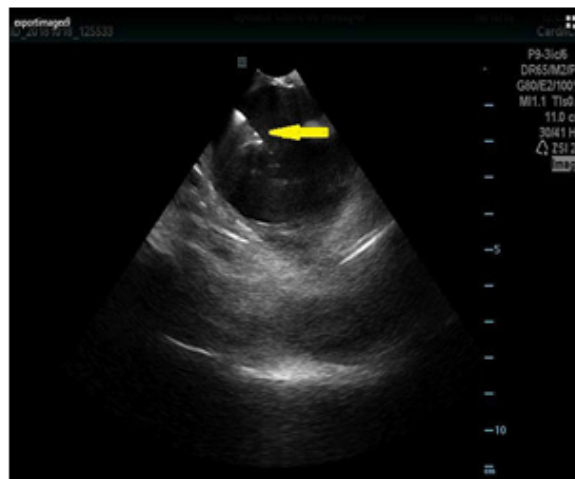
**Figure 5.12:** Intracardiac echocardiography. In this view the interatrial septum can be seen in the same plane with the right inferior vein. In this plane is not safe to perform transseptal puncture as it is too posterior with a theoretical risk of puncturing the posterior wall of the left atrium.



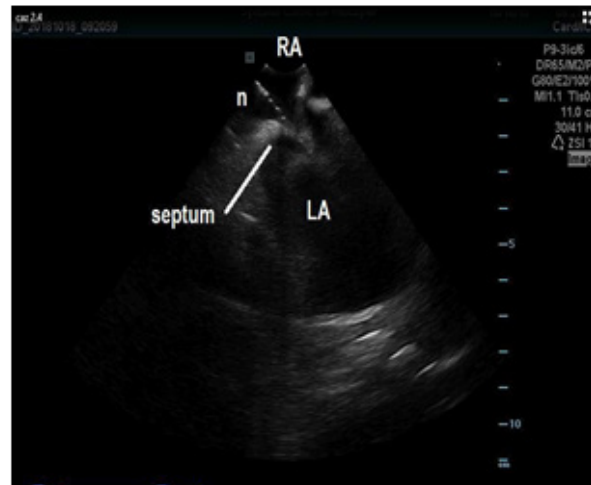
**Figure 5.13:** Intracardiac echocardiography during catheter ablation of atrial fibrillation. The transeptal puncture is guided by ICE to obtain access to the left atrium. The needle is against the interatrial septum at the level of fossa ovalis. The thin part of the interatrial septum is called fossa ovalis. The “tenting” of the interatrial septum signifies a stable contact of the needle with the fossa ovalis. The puncture should be performed in the same plane with LSPV.



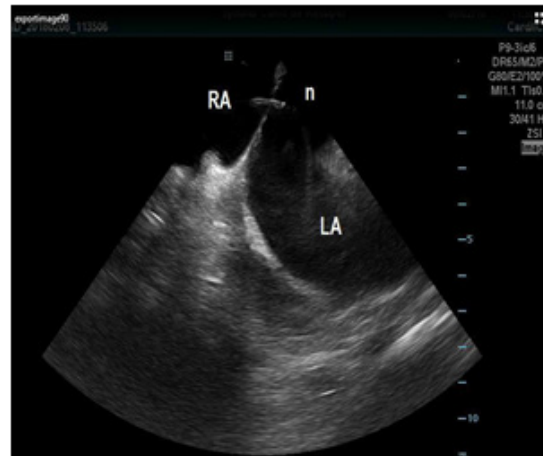
**Figure 5.14:** Intracardiac echocardiography during catheter ablation of atrial fibrillation. The transeptal puncture is guided by ICE to obtain access to the left atrium. The white arrow indicated the transeptal needle against the interatrial septum at the level of fossa ovalis. The “tenting” of the interatrial septum signifies a stable contact of the needle with the fossa ovalis.



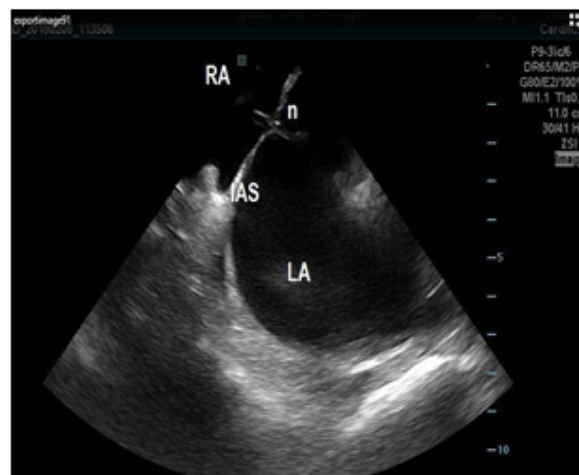
**Figure 5.15:** Intracardiac echocardiography with the probe inserted in the middle of the right atrium. Tenting of the fossa ovalis with the transeptal puncture (yellow arrow).



**Figure 5.16:** Intracardiac echocardiography during catheter ablation of atrial fibrillation. The transseptal puncture is guided by ICE to obtain access to the left atrium. The white arrow indicated the transseptal needle against the interatrial septum at the level of fossa ovalis. The “tenting” of the interatrial septum signifies a stable contact of the needle with the fossa ovalis.

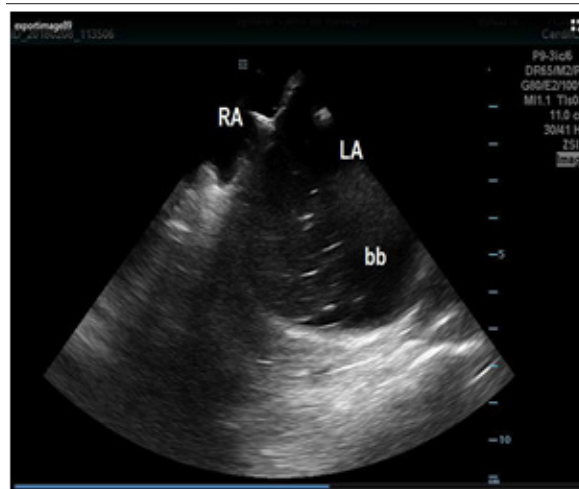


**Figure 5.17:** Intracardiac echocardiography during catheter ablation of atrial fibrillation. The needle passed inside the left atrium. RA=right atrium; LA=left atrium; n=transseptal needle; The thin part of the interatrial septum is called fossa ovalis.

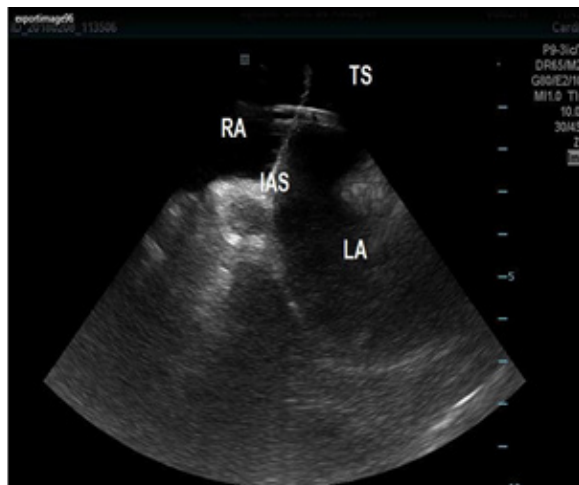


**Figure 5.18:** Intracardiac echocardiography during catheter ablation of atrial fibrillation. The transseptal puncture is guided by ICE to obtain access to the left atrium. The needle is against the interatrial septum at the level of fossa ovalis. The “tenting” of the interatrial septum signifies a stable contact of the needle with the fossa ovalis. The needle passed in the left atrium. RA=right atrium; LA=left atrium; n=transseptal needle; IAS=interatrial septum. The thin part of the interatrial septum is called fossa ovalis.

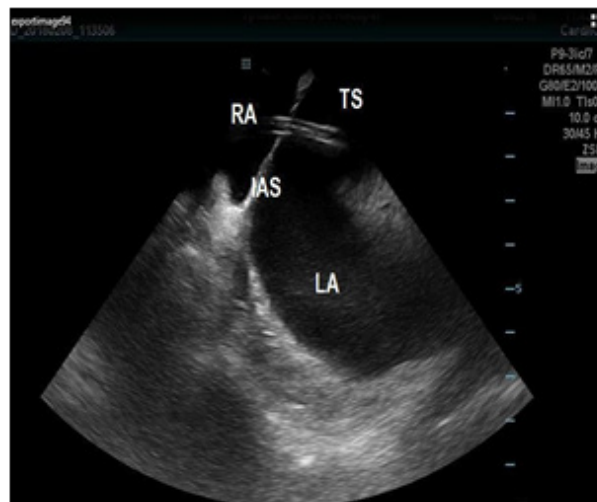




**Figure 5.19:** Intracardiac echocardiography during catheter ablation of atrial fibrillation. The needle passed inside the left atrium. The presence of bubbles inside the left atrium is an indirect sign of a successful transeptal puncture. RA=right atrium; LA=left atrium; bb=serum bubbles.

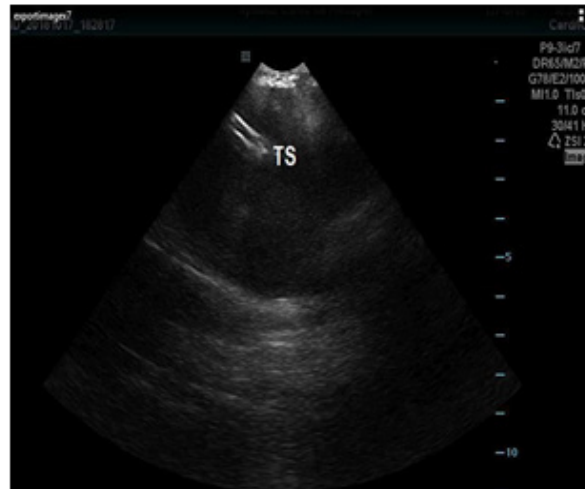


**Figure 5.20:** Intracardiac echocardiography with the ViewFlex probe inserted in the middle of the right atrium. The transseptal sheath passes through the interatrial septum in the left atrium. RA=right atrium; TS=transseptal sheath; LA=left atrium; IAS=interatrial septum.

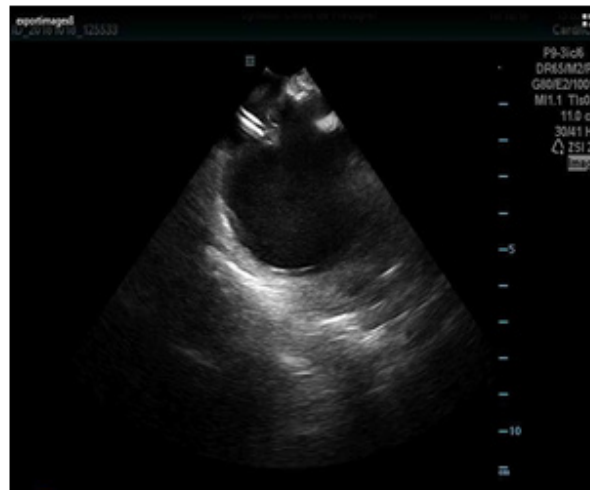


**Figure 5.21:** Intracardiac echocardiography with the ViewFlex probe inserted in the middle of the right atrium. The transseptal sheath passes through the interatrial septum in the left atrium. Please note that the sheath passes through the thinnest part of the septum which is the fossa ovalis.

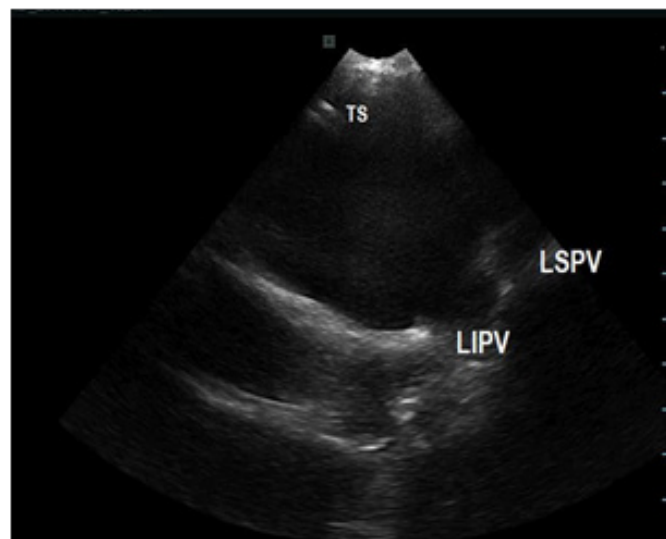




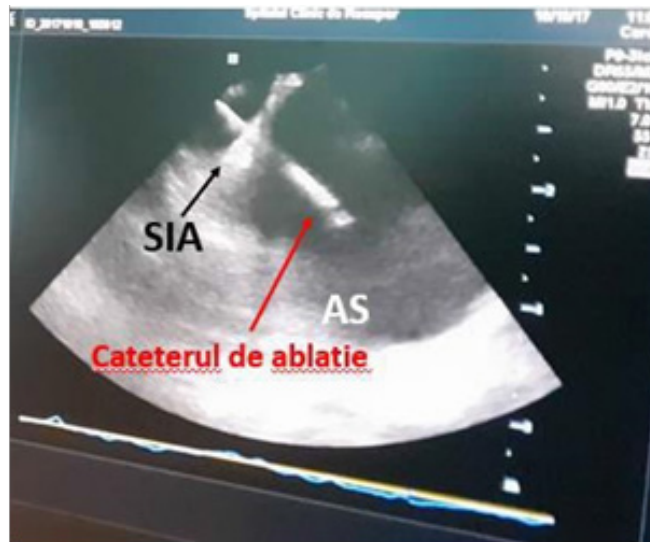**Figure 5.22:** Intracardiac echocardiography with the probe inserted in the middle of the right atrium. The transseptal sheath is visible at the level of the left atrium. TS=transseptal sheath.



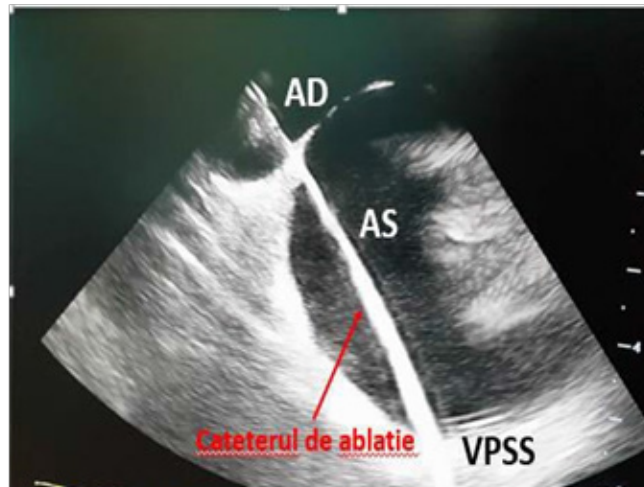
**Figure 5.23:** Intracardiac echocardiography with the probe inserted in the middle of the right atrium. The transseptal puncture was performed and a guidewire is inserted inside the left atrium. In this image, in the same plane is visible a common left trunk.



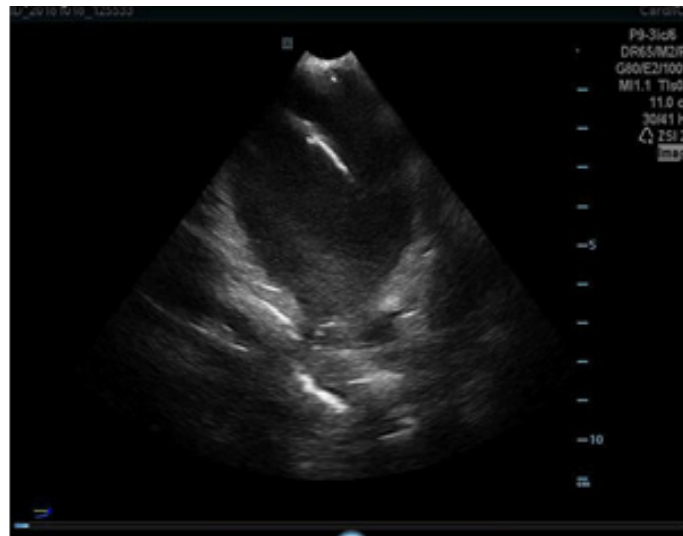**Figure 5.24:** Intracardiac echocardiography with the probe inserted in the middle of the right atrium. The transseptal sheath is visible at the level of the left atrium. In the same image LSPV and LIPV are visible, an important detail for transseptal puncture.



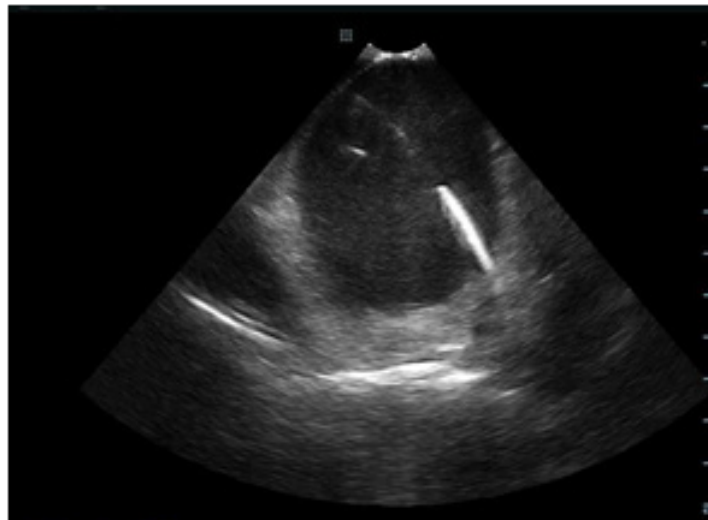
**Figure 5.25:** Intracardiac echocardiography during pulmonary vein isolation. The ablation catheter is situated inside the left atrium. It passes the interatrial septum at the level of fossa ovalis.



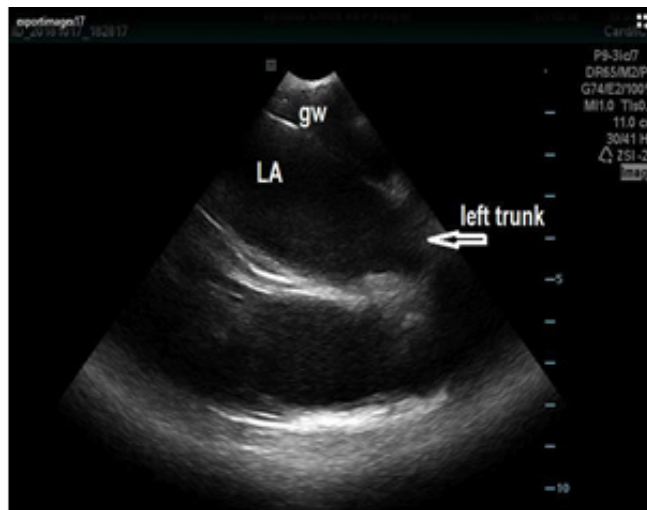
**Figure 5.26:** Intracardiac echocardiography during pulmonary vein isolation. The ablation catheter is situated inside the left superior pulmonary vein. It passes through the interatrial septum at the level of fossa ovalis.



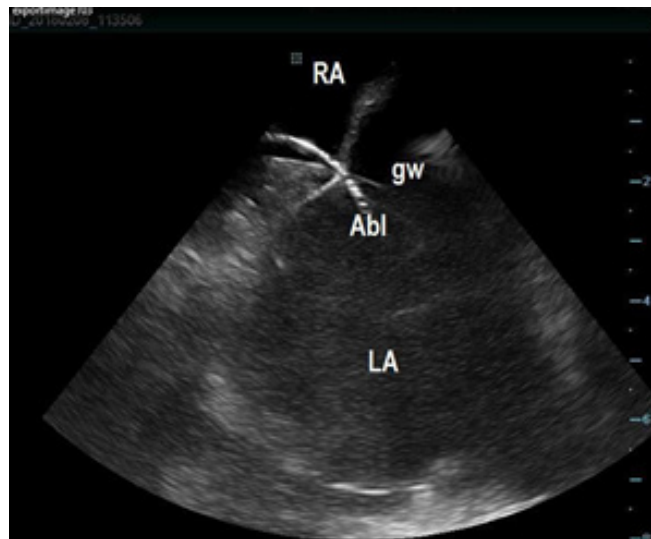
**Figure 5.27:** Intracardiac echocardiography with the probe inserted in the middle of the right atrium. A guidewire is visible at the level of the left atrium, in the middle of it.



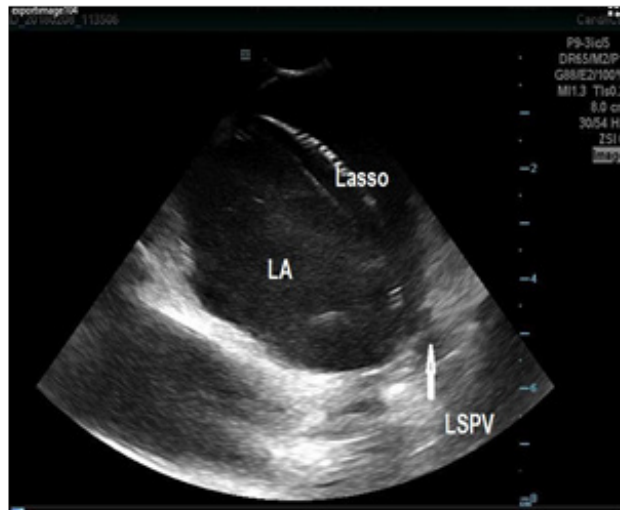
**Figure 5.28:** Intracardiac echocardiography with the probe inserted in the middle of the right atrium. A guidewire is inserted at the level of the left superior pulmonary vein.



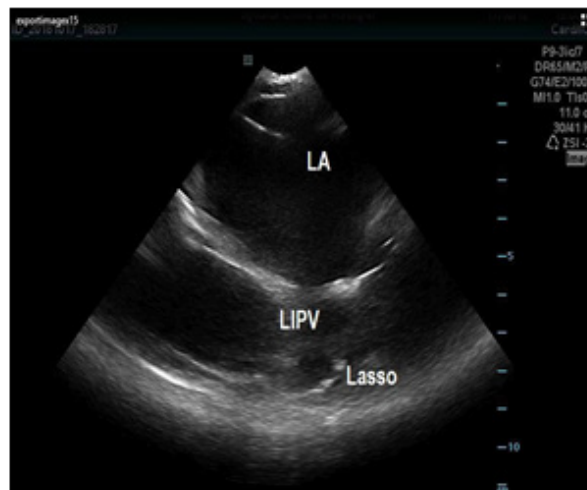
**Figure 5.29:** Intracardiac echocardiography with the probe inserted in the middle of the right atrium. A guidewire is visible at the level of the left atrium. In this image a common trunk is visible at the level of left veins.



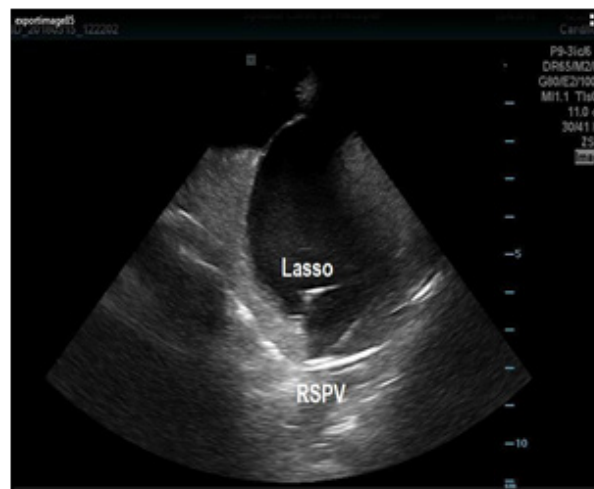
**Figure 5.30:** Intracardiac echocardiography with the echo probe inserted in the middle of the right atrium. A guidewire and the catheter ablation are passing through the interatrial septum. LA=left atrium; gw=guidewire, Abl=ablation catheter; RA=right atrium



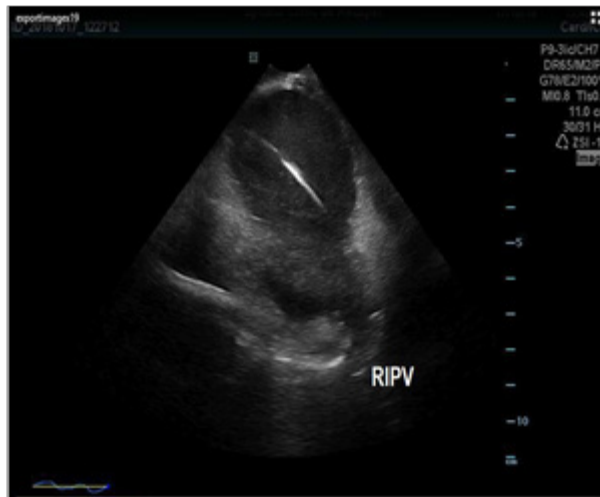
**Figure 5.31:** Intracardiac echocardiography with the echo probe inserted in the middle of the right atrium. A Lasso catheter is introduced at the level of the left superior pulmonary vein. LA=left atrium; LSPV=left superior pulmonary vein; Lasso=Lasso catheter.



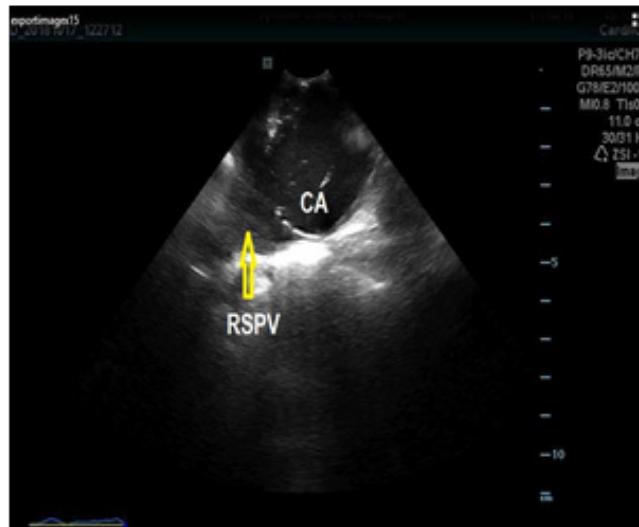
**Figure 5.32:** Intracardiac echocardiography with the probe inserted in the middle of the right atrium. Passing the left atrium, a Lasso catheter is seen, with the circular part being inside the LIPV. LA=left atrium, LIPV=left inferior pulmonary vein Lasso=Lasso catheter.



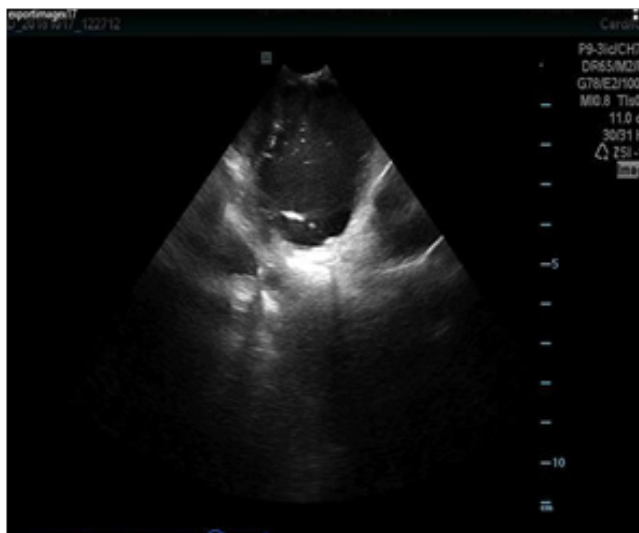
**Figure 5.33:** Intracardiac echocardiography with the probe inserted in the middle of the right atrium. The Lasso ablation is placed near the antrum of the right superior pulmonary vein.



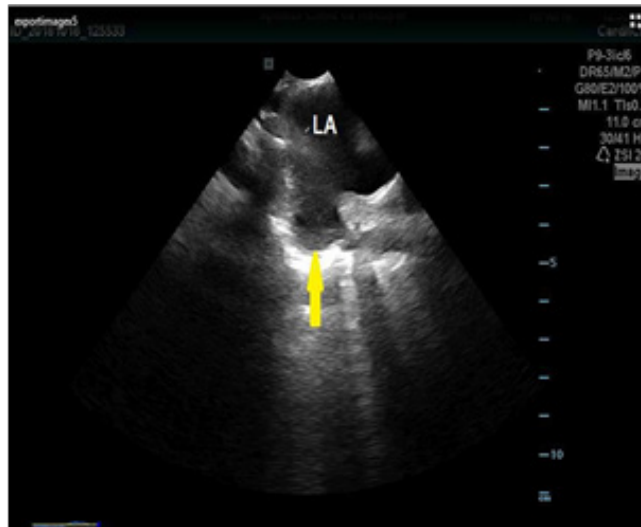
**Figure 5.34:** Intracardiac echocardiography with the probe inserted in the middle of the right atrium. The catheter ablation is placed near the right inferior pulmonary vein, at the level of the antrum.



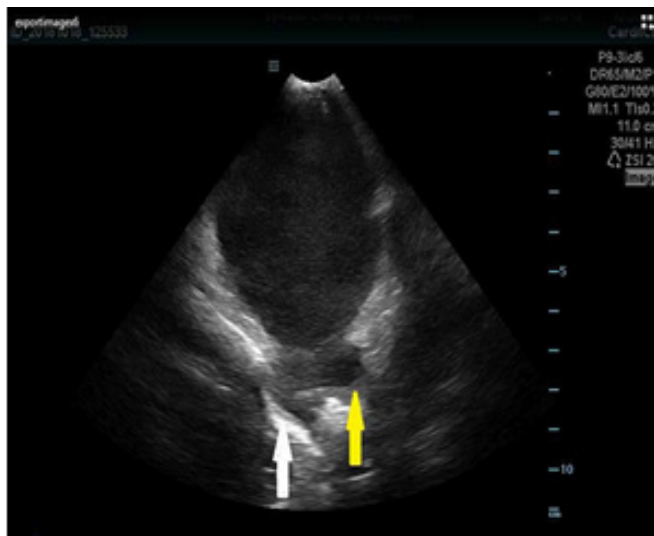
**Figure 5.35:** Intracardiac echocardiography with the probe inserted in the middle of the right atrium. The catheter ablation is placed near the right inferior pulmonary vein, which is not visible on this image. RSPV is visible (yellow arrow).



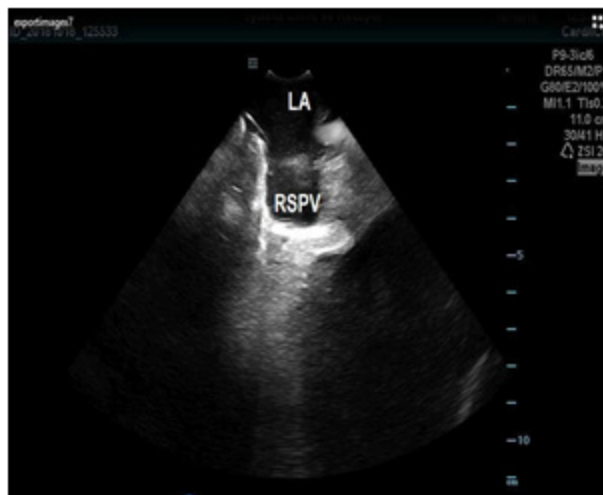
**Figure 5.36:** Intracardiac echocardiography with the probe inserted in the middle of the right atrium. The catheter ablation is placed near the right inferior pulmonary vein, which is not visible on this image.



**Figure 5.37:** Intracardiac echocardiography with the probe inserted in the middle of the right atrium in this image the RSPV is visible (yellow arrow).

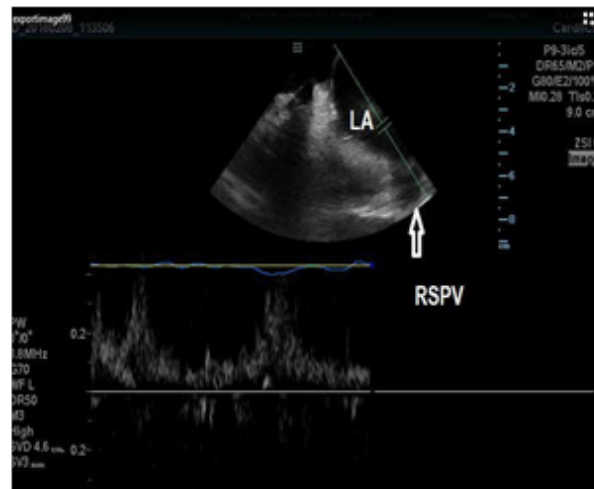


**Figure 5.38:** Intracardiac echocardiography with the probe inserted in the middle of the right atrium. Both LSPV and LIPV are visible, forming a common trunk before the drainage to the left atrium. White arrow -LIPV, yellow arrow-LSPV.

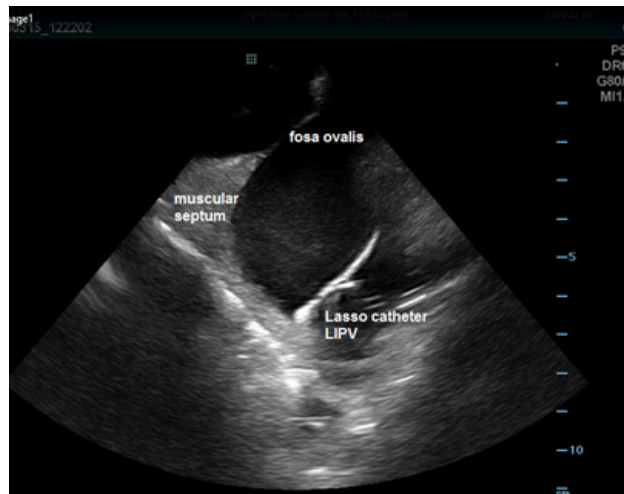


**Figure 5.39:** Intracardiac echocardiography with the probe inserted in the middle of the right atrium. A dilated RSPV can be seen emerging from the LA.

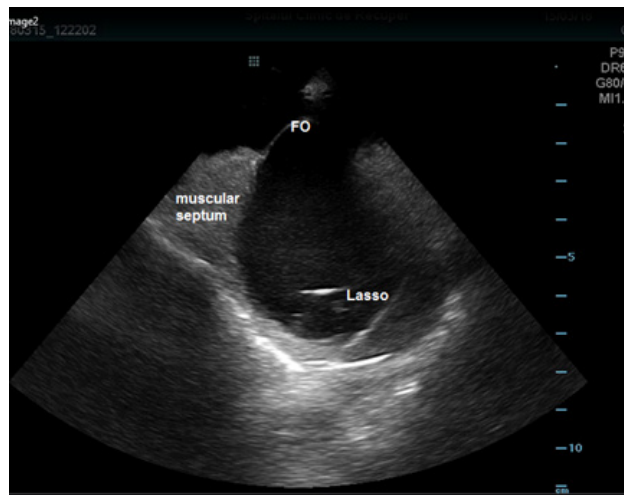




**Figure 5.40:** Intracardiac echocardiography with the echo probe inserted in the middle of the right atrium. Pulsed Doppler flow at the level of right superior pulmonary vein.

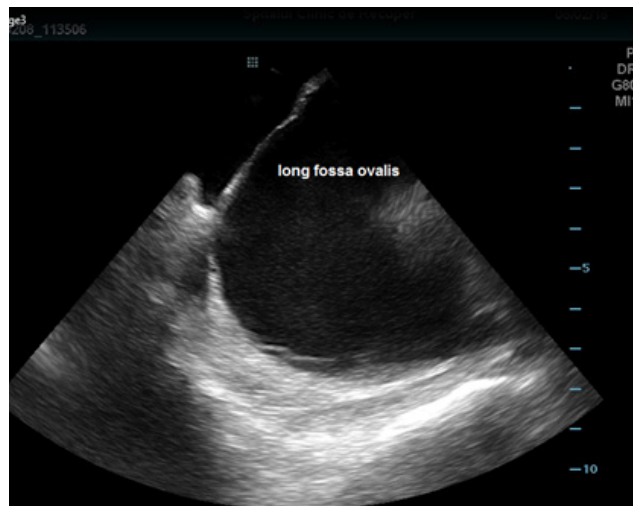


**Figure 5.41:** Intracardiac echocardiography to guide transseptal puncture. The interatrial septum has a muscular structure (thick muscular septum) and fibro-elastic structure in the middle of it (fossa ovalis). The puncture should be performed at the level of the fossa ovalis. The Lasso catheter is inside the LIPV.

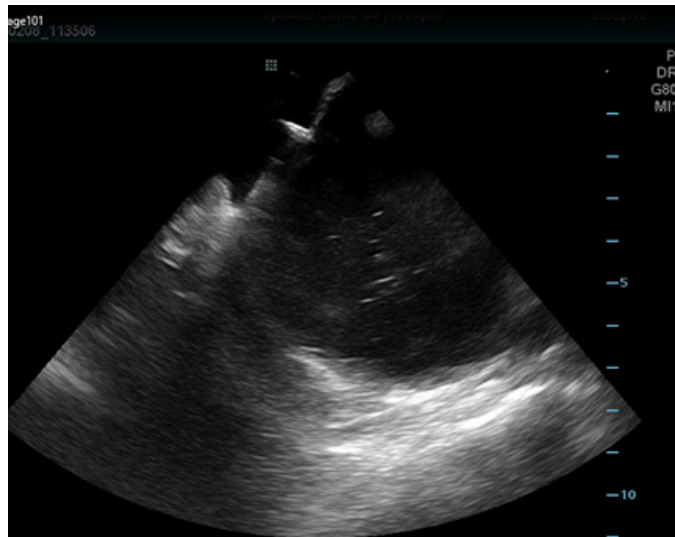


**Figure 5.42:** Intracardiac echocardiography to guide transseptal puncture. The interatrial septum has a muscular structure (thick muscular septum) and fibro-elastic structure in the middle of it (fossa ovalis). The puncture should be performed at the level of the fossa ovalis. The Lasso catheter is at the level of the antrum of the LIPV guiding electrical isolation of the vein.

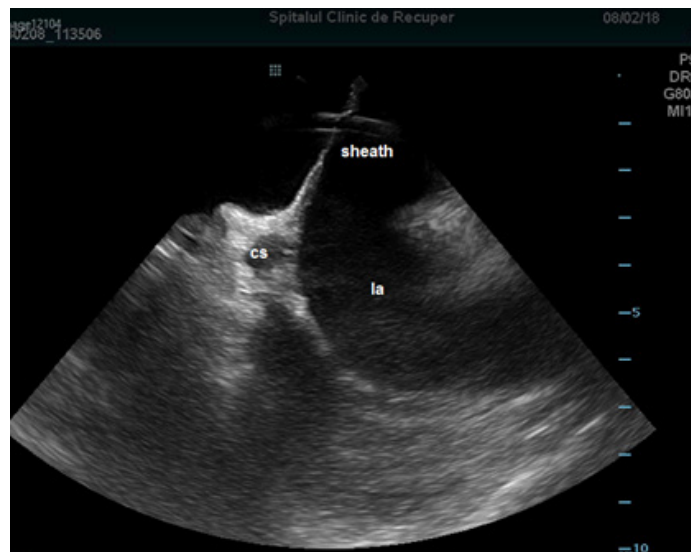




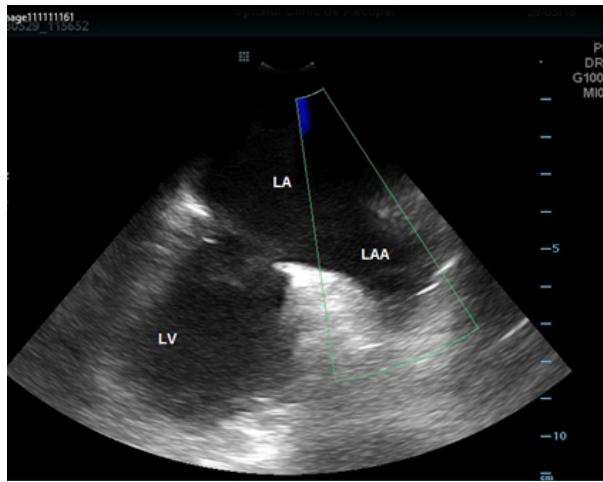
**Figure 5.43:** Intracardiac echocardiography to guide transseptal puncture. This septum has a different structure compared to the previous. It is thinner with a long fossa ovalis.



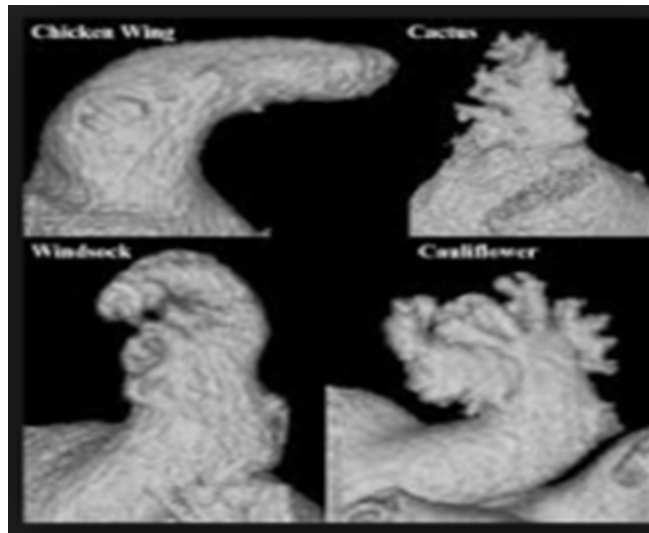
**Figure 5.44:** Intracardiac echocardiography to guide transseptal puncture. Presence of bubbles inside the LA is a sign that the needle passed in the LA.



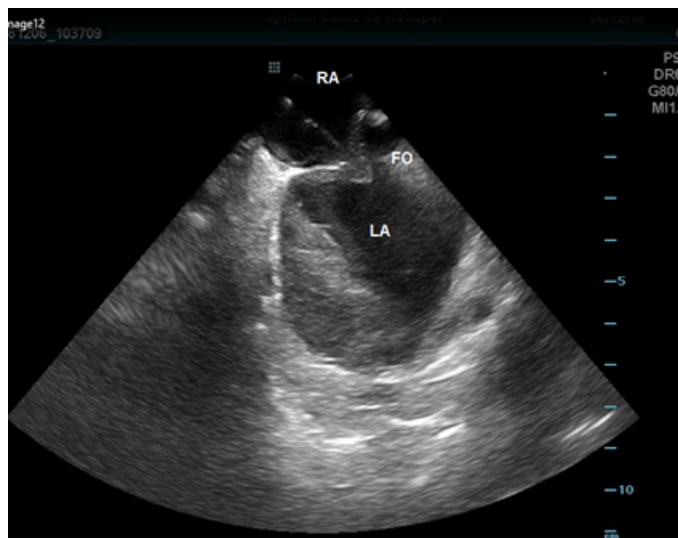
**Figure 5.45:** Intracardiac echocardiography to guide transseptal puncture. The sheath is introduced inside the left atrium and the needle is retracted outside the body. CS=coronary sinus; LA=left atrium. Sheath=transseptal sheath.



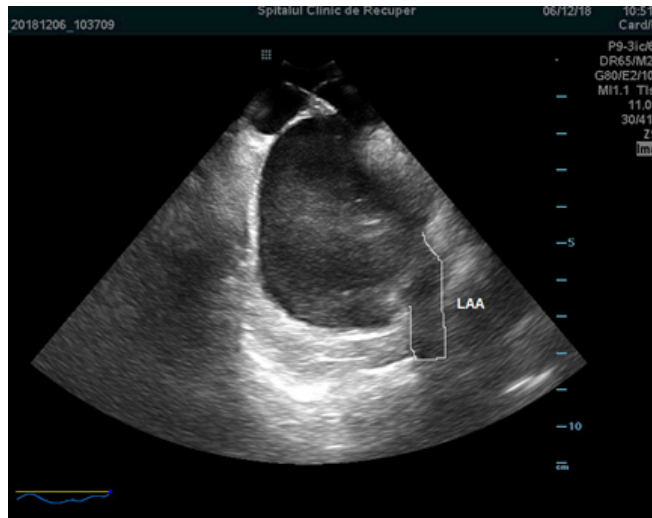
**Figure 5.46:** Intracardiac echocardiography to guide transseptal puncture. A counter clockwise rotation from the septal view will bring the left atrial appendage into image. At this level a thrombus should be excluded; furthermore, the flow in the left appendage can be evaluated using pulsed Doppler.



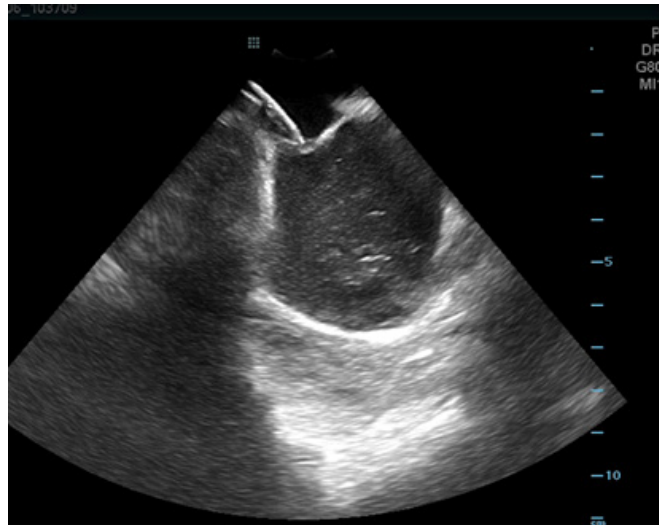
**Figure 5.47:** Types of left atrial appendage in function of the morphology: chicken wing, cactus, windsack, cauliflower. Di Biase [12].



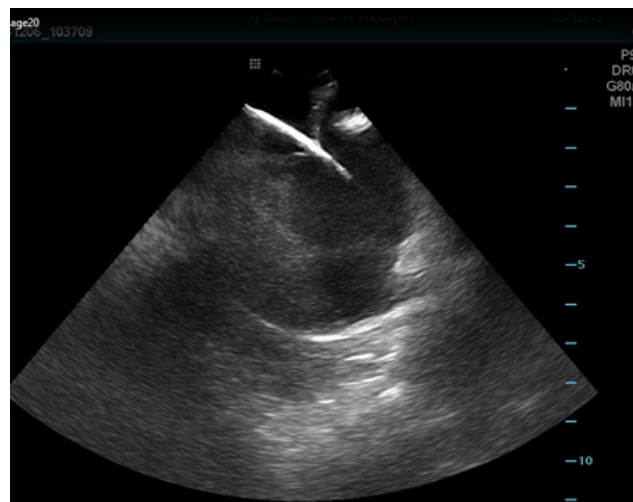**Figure 5.48:** Intracardiac echocardiography to guide transseptal puncture. The needle is against the fossa ovalis which gives the “tenting” image. LA=left atrium; FO=fossa ovalis; RA=right atrium.



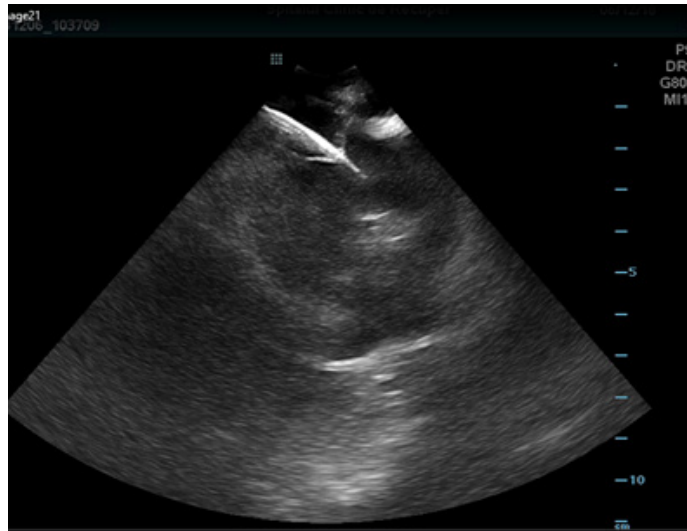**Figure 5.49:** Intracardiac echocardiography to guide transseptal puncture. From the “septal view” a counter clockwise rotation of the probe will bring the left atrial appendage into image.



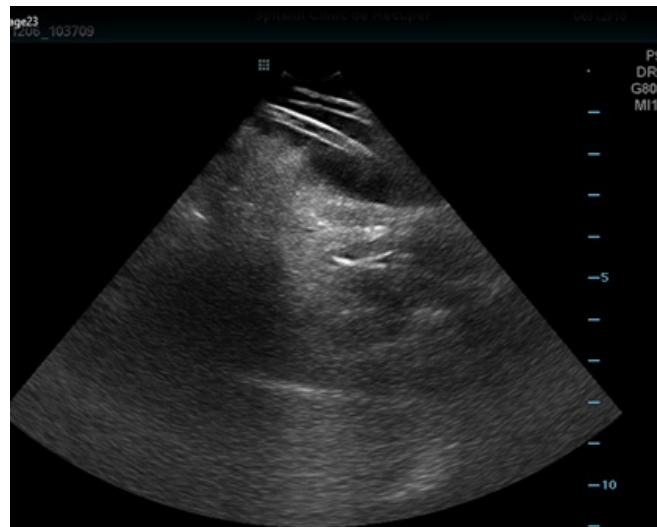**Figure 5.50:** Intracardiac echocardiography to guide transseptal puncture. The presence of bubbles inside the left atrium is a sign of successful transseptal puncture.



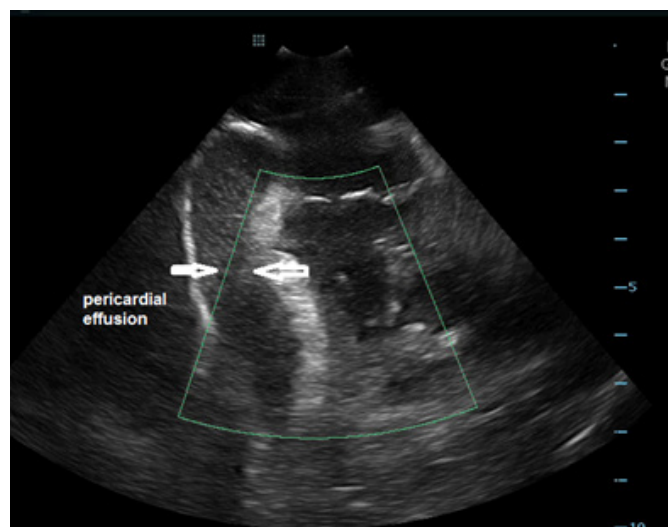
**Figure 5.51:** Intracardiac echocardiography to guide transseptal puncture. Tenting of the fossa ovalis and introduction of the guidewire inside the left atrium.



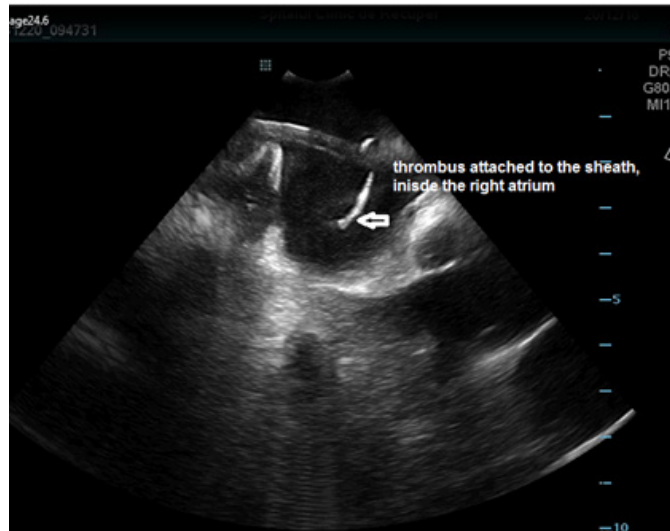**Figure 5.52:** Intracardiac echocardiography to guide transseptal puncture. Tenting of the fossa ovalis and introduction of the needle inside the left atrium.



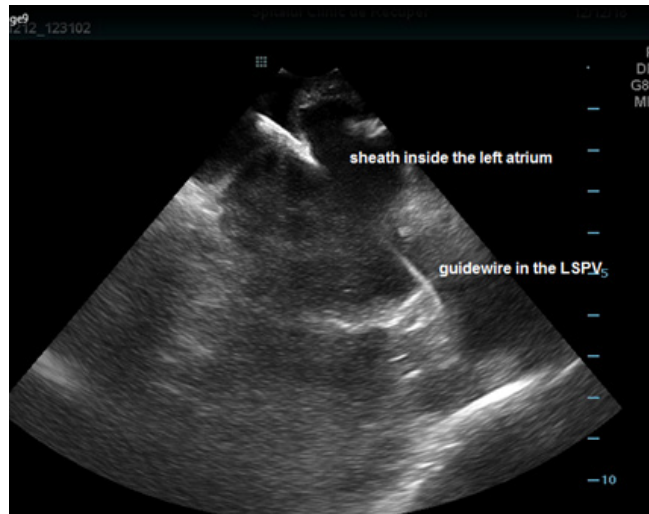
**Figure 5.53:** Intracardiac echocardiography to guide transseptal puncture. Two sheaths are introduced inside the left atrium.



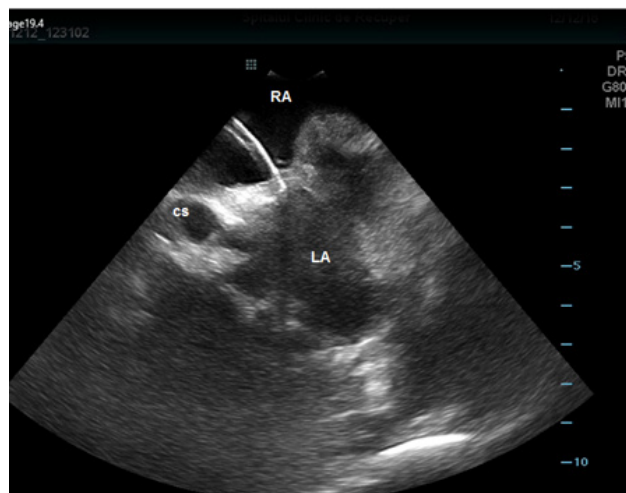
**Figure 5.54:** Intracardiac echocardiography to guide transseptal puncture. “Home view”. After transseptal puncture fluid can be seen lateral to the right ventricle. The procedure was interrupted, and Protamine injected through a peripheral vein.



**Figure 5.55:** Intracardiac echocardiography to guide catheter ablation of atrial fibrillation. A linear thrombus can be visualized on the right atrial side of the septum. The thrombus is attached to the transeptal sheath. It has a theoretical risk of embolization to the pulmonary artery and lungs.

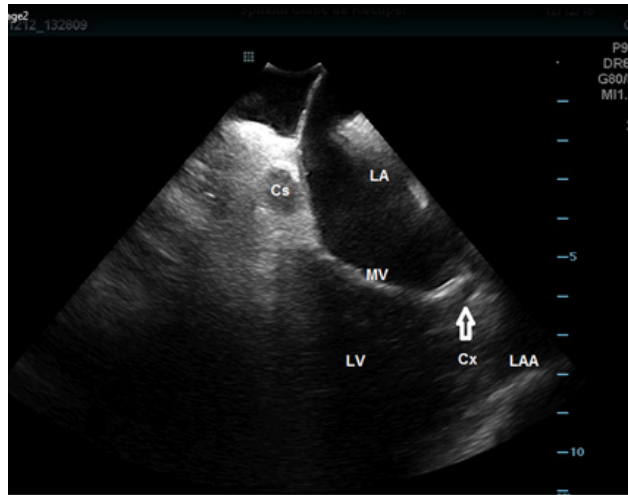


**Figure 5.56:** Intracardiac echocardiography to guide transeptal puncture. The sheath is inside the left atrium and the guidewire inside the left superior pulmonary vein.

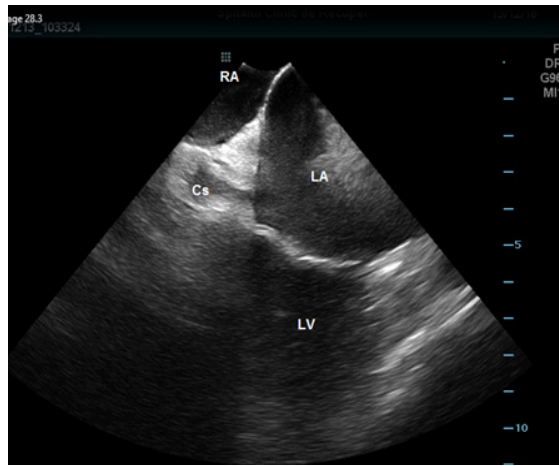


**Figure 5.57:** Intracardiac echocardiography to guide transeptal puncture. Please remark the moderate dilation of the coronary sinus (CS).

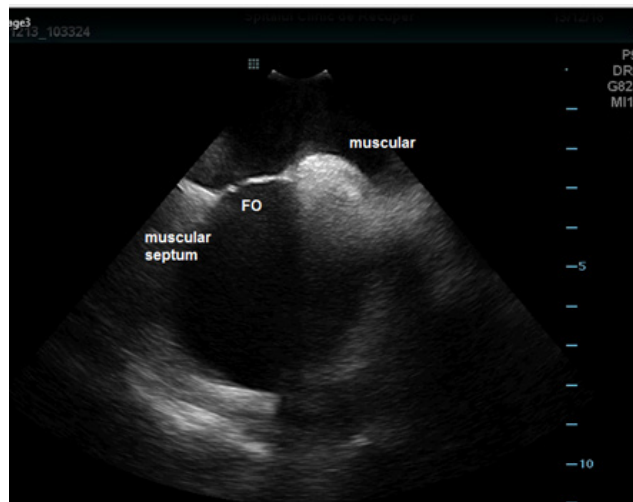




**Figure 5.58:** Intracardiac echocardiography to guide transseptal puncture. This is the “septal view” with counterclockwise rotation. Therefore, the left ventricle (LV) and the mitral valve can be visualized. The coronary sinus is seen (Cs) under the right atrium. Both the circumflex artery (Cx) and the left atrial appendage (LAA) can be visualized in the right part of the image.



**Figure 5.59:** Intracardiac echocardiography to guide transseptal puncture. This is the septal view with counterclockwise rotation. Therefore, the left ventricle (LV) and the mitral valve can be visualized. The coronary sinus is seen (Cs) under the right atrium. In this image circumflex artery cannot be visualized. The mitral valve is closed.



**Figure 5.60:** Intracardiac echocardiography to guide transseptal puncture. In the upper part of the image the right atrium can be found and in the lower part the left atrium. The middle part of the interatrial septum is the fibroelastic part which is called the fossa ovalis. Right and left to the fossa ovalis lies the muscular part of the interatrial septum.



Some advantages of the ICE technique over TTE and TEE are:

a) Patient discomfort is less and general anesthesia routinely is not needed, communication with the patient during the procedure is possible, the transducer is not necessary to be positioned in a sterile field as compared to TTE, it gives direct information on the exact position of the catheters inside the heart and it can monitor acute complications related to the procedure such as: cardiac tamponade or thrombus formation.

b) Like any other invasive procedure, it has some limitations: it needs a considerable shaft size of 10F, it lacks additional catheter features like those used in angiography: ports for guidewires, pressure monitoring and therapeutic devices. Furthermore, the phased array probes are expensive and are for single use only, between several operators it is difficult to obtain the same image sections, phased array probes permit only monoplane image sections and there are no standard views like in TTE or TEE.

Future advances for ICE technology will permit integration of ultrasound imaging with mapping technologies, fusion and overlay of the obtained images with the computer tomography of the patient or the electro anatomical map.

# Chapter 6

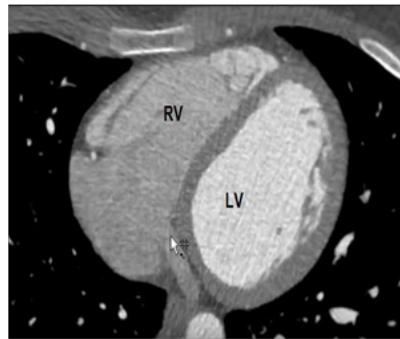
## Computed Tomography of the Left Atrium

Left atrium and pulmonary veins are seen in CT with an excellent spatial resolution. Multi-slice CT has a good spatial and temporal resolution and the volume of the LA can be easily measured. It is not routinely used to measure LA size because of radiation exposure and use of iodinated contrast agents. Computed tomography provides detailed information on the LA and pulmonary vein anatomy, being the method of choice to describe anomalies of the pulmonary veins: common trunk, additional right pulmonary vein. The veno-atrial junction and the ridge between LSPV and LAA are critical structures that need to be identified during catheter ablation. The ostia of the four pulmonary veins can be measured and compared to the diameter of the Lasso catheter: 15mm or 25mm or with the diameter of the cryoballoon (23 or 28mm). Computed tomography also identifies presence of a LAA thrombus and provides information on the neighbouring structures: esophagus, aorta, coronary arteries and coronary sinus.

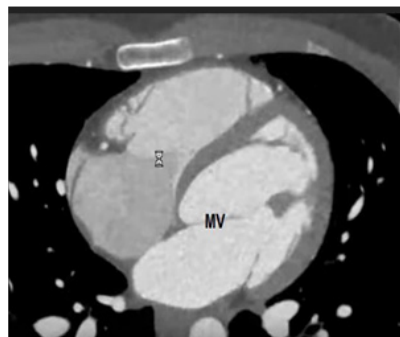
CT of the left atrium should include measurements of diameters: infero-superior, latero-lateral and anteroposterior, surface and volume of the LA. Furthermore, a thrombosis of the LA or LAA should be excluded during the exam. The last and important information given by the CT is the number of the pulmonary veins and their connections with the left atrium.

Before the ablation procedure, the interatrial septum should also be evaluated with CT. The angle with the line that connects the sternum with the dorsal column is important for the orientation of the needle during transseptal puncture. The dimensions and orientation of the fossa ovalis should also be evaluated as well as the presence of adipose tissue at this level. Sometimes a patent foramen ovale may be present, in such cases the ablation catheter can be inserted inside the left atrium using this route.

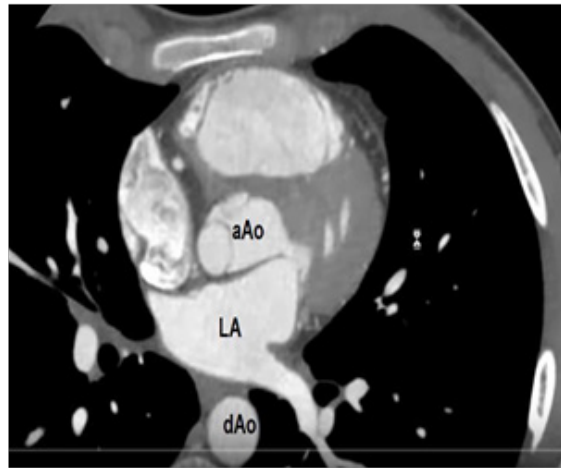
After catheter ablation, if the patient needs a second procedure, CT can evaluate the presence of pulmonary stenosis by comparing the diameters of the pulmonary veins before and after catheter ablation (Figure 6.1-6.44).



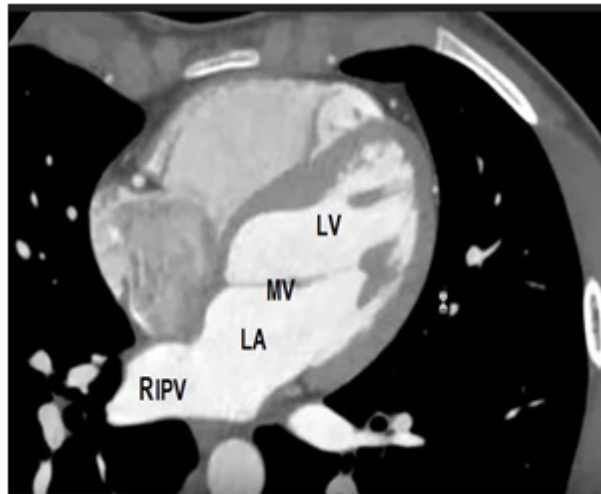
**Figure 6.1:** Computed tomography of the heart. Left atrium cannot be visible on this image. Both LV and RV are visible.



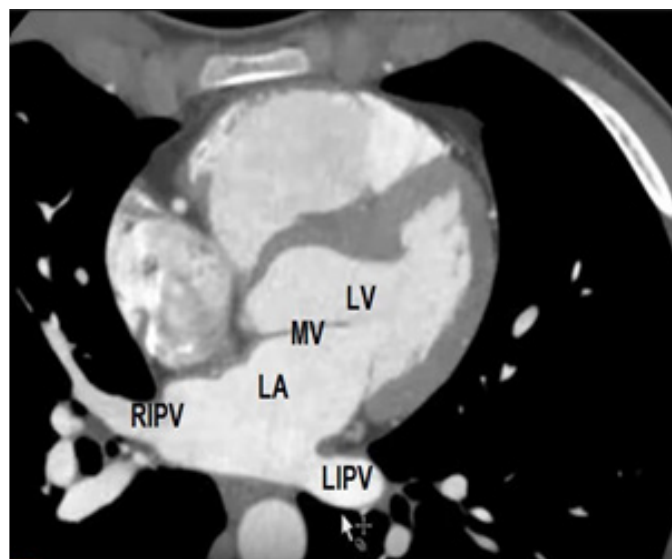
**Figure 6.2:** Computed tomography of the heart. The mitral valve is visible between the left atrium and left ventricle, but the emergence of the pulmonary veins is not visible at this low plan section.



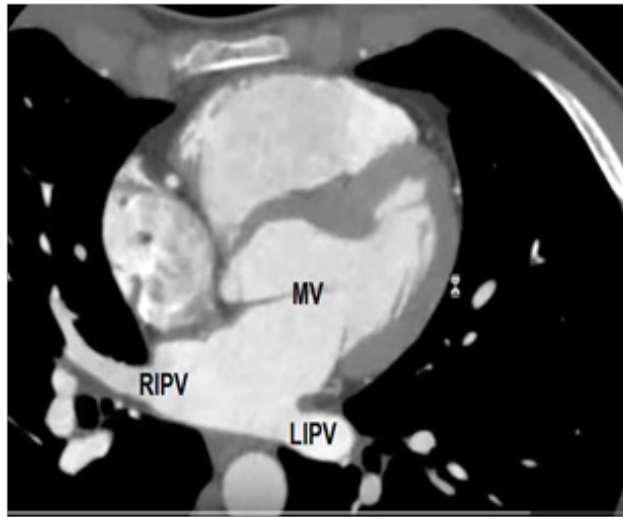
**Figure 6.3:** Computed tomography of the heart. The left atrium is a posterior structure. It is situated between the ascendant aorta and the descendant aorta. aAo=ascendant aorta; dAo=descendant aorta; LA=left atrium.



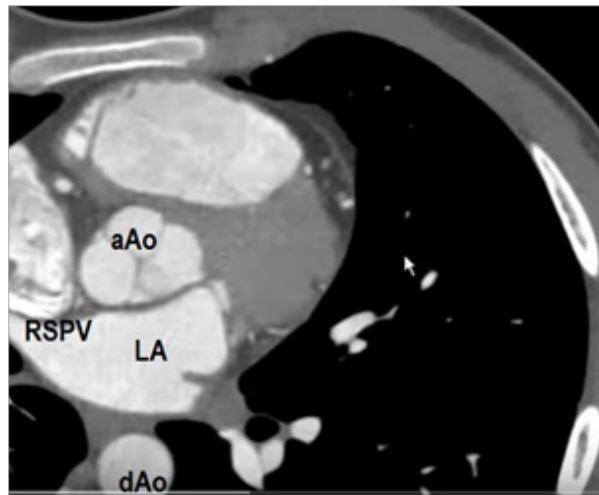
**Figure 6.4:** Computed tomography of the heart. The left atrium is a posterior structure. The mitral valve can be seen between the left ventricle and the left atrium. The vein that is seen in the image is the RIPV as it is situated in the inferior part of the atrium, in the same plan with the mitral valve.



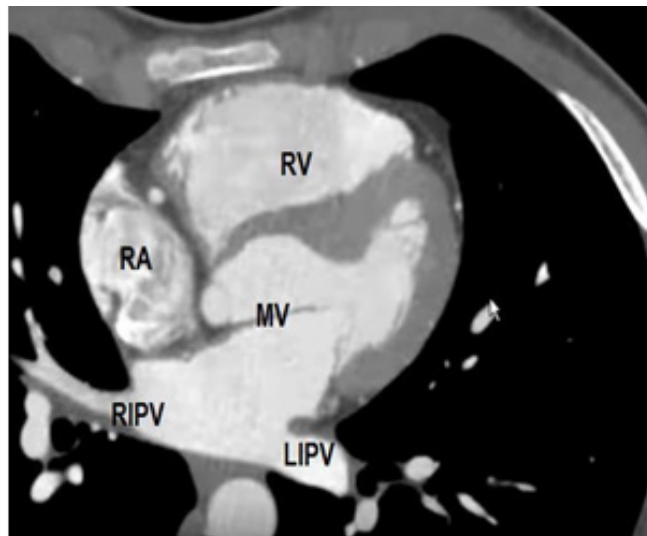
**Figure 6.5:** Computed tomography of the heart. The image shows both inferior pulmonary veins that can be found in the same plan with the mitral valve.



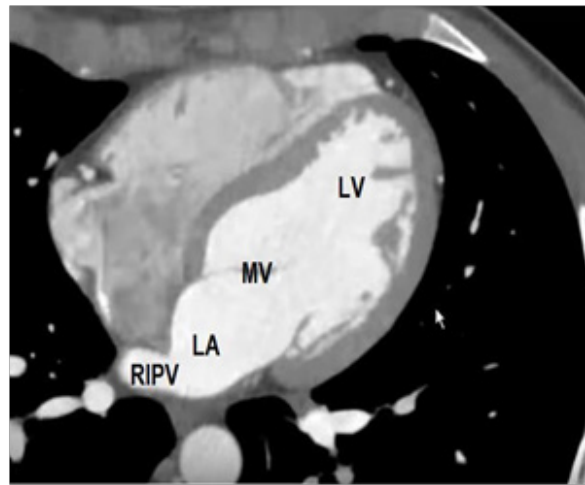
**Figure 6.6:** Computed tomography of the heart. The mitral valve is visible between the left atrium and left ventricle. Both inferior pulmonary veins are visible: LIPV and RIPV.



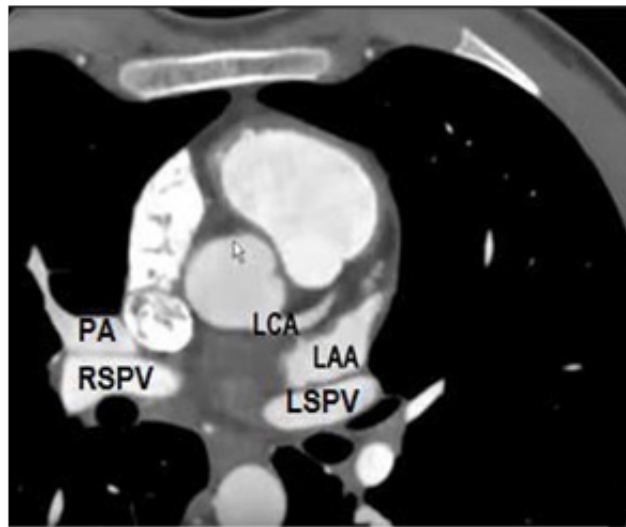
**Figure 6.7:** Computed tomography of the heart. The left atrium is a posterior structure situated between the ascending aorta and the descendant aorta. RSPV is visible in the image and goes behind the right atrium and superior vena cava.



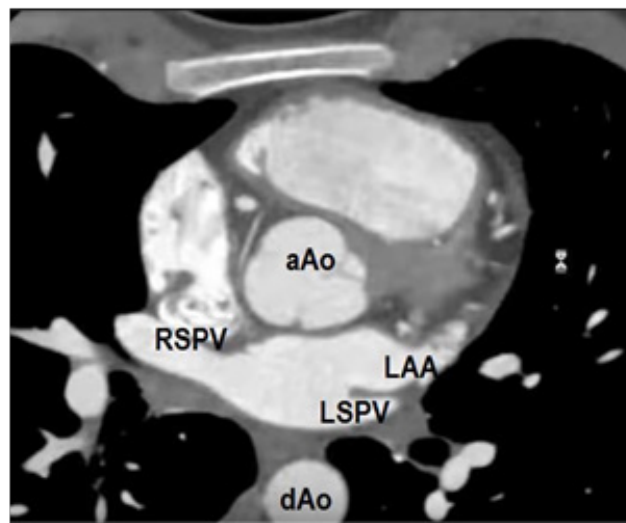
**Figure 6.8:** Computed tomography of the heart. The mitral valve is visible between the left atrium and left ventricle. Both inferior pulmonary veins are visible: LIPV and RIPV.



**Figure 6.9:** Computed tomography of the heart. The mitral valve is visible between the left atrium and left ventricle. The mitral valve is opened.

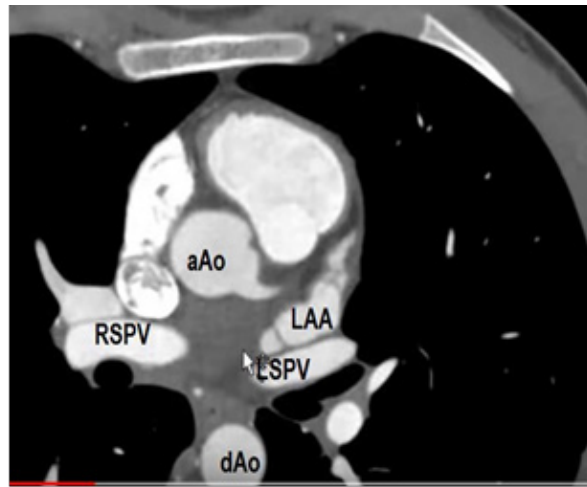


**Figure 6.10:** Computed tomography of the heart. The left atrial appendage can be visualized on the left side of LA. It is an anterior structure. The vein close to LAA is the LSPV and the vein on the right side is the RSPV. Inferior veins cannot be seen in the same plane with the LAA. The right pulmonary artery (PA) is close to RSPV.

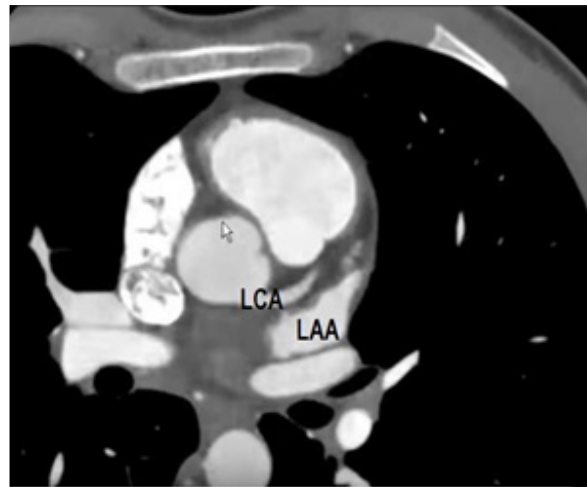


**Figure 6.11:** Computed tomography of the heart. The image shows both superior pulmonary veins that can be found in the same plan with the left atrial appendage and the ascending aorta. LAA is trabeculated therefore the contrast cannot completely fill the LAA in its distal portion.

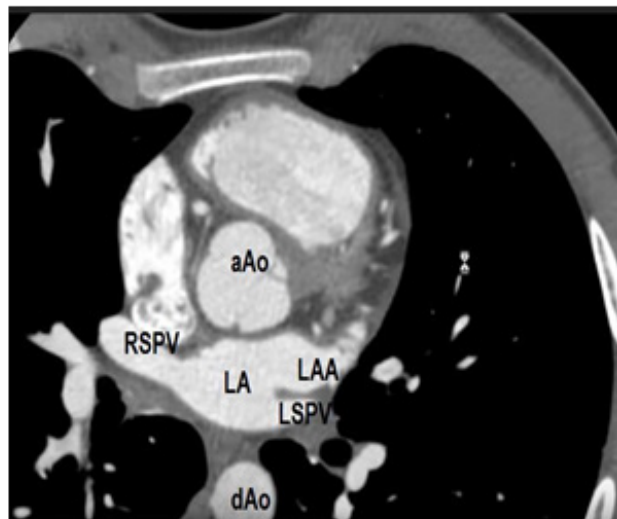




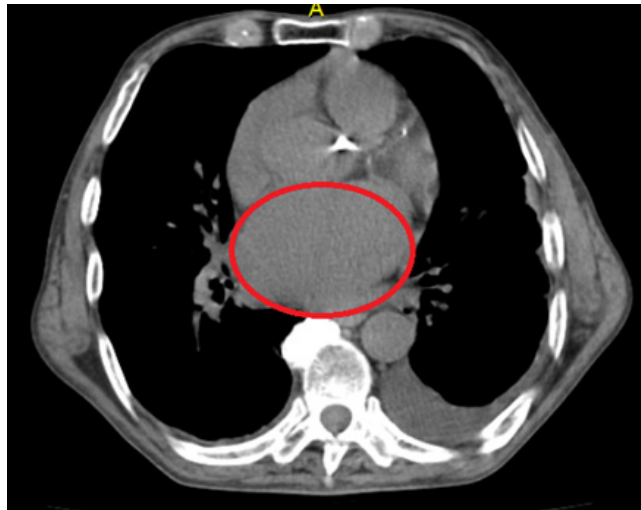
**Figure 6.12:** Computed tomography of the heart. The image shows both superior pulmonary veins that can be found in the same plan with the left atrial appendage and the ascending aorta. Please note the emergence of the left coronary artery at the level of the left coronary cusp. LAA is trabeculated therefore the contrast cannot completely fill the LAA in its distal portion.



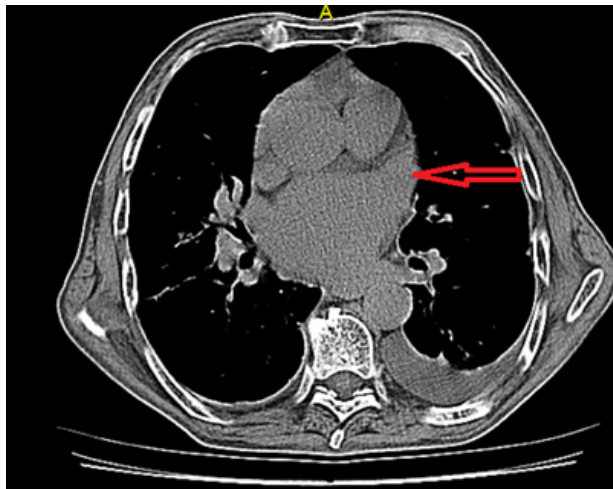
**Figure 6.13:** Computed tomography of the heart. The image shows the left atrial appendage and its close relationship with the left coronary artery (LCA) as it starts from the ascendant aorta at the level of left coronary cusp.



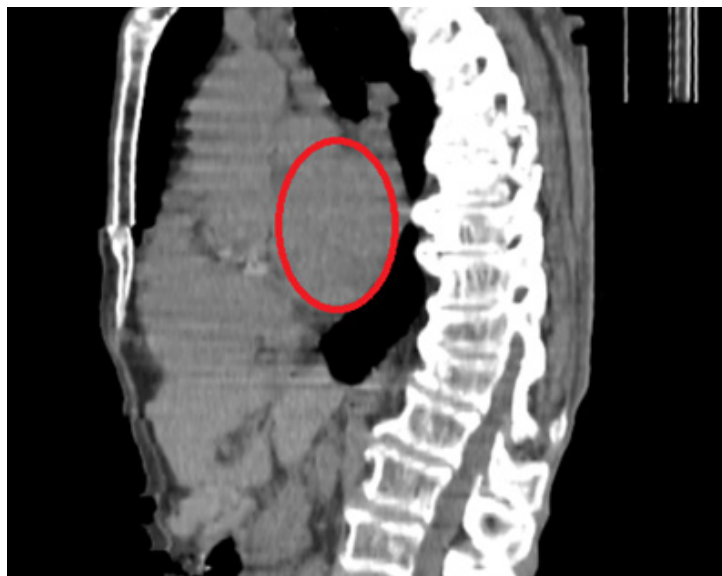**Figure 6.14:** Computed tomography of the heart. The left atrium is a posterior structure situated between the ascendant aorta and the descendant aorta. Left atrial appendage can be seen in the left lateral anterior region of the LA. Please note the trabeculations at the apex of the LAA, the contrast substance not being able to fully fill the LAA.



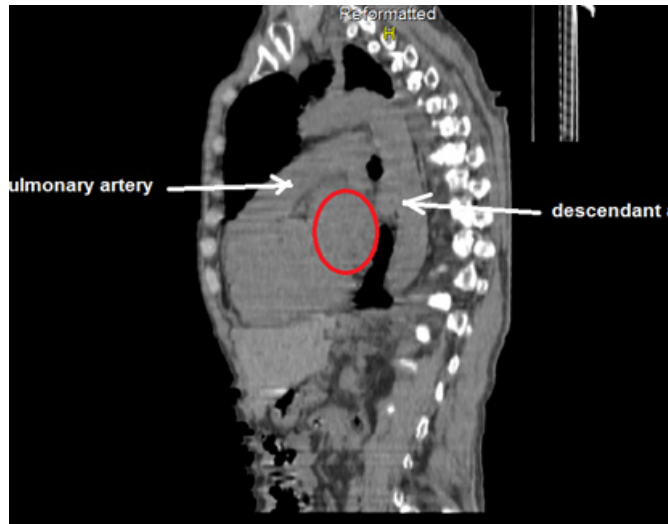
**Figure 6.15:** Computed tomography of the heart. The left atrium is a posterior structure and usually it is not visible on a chest X-ray. In case of dilation, it will become visible.



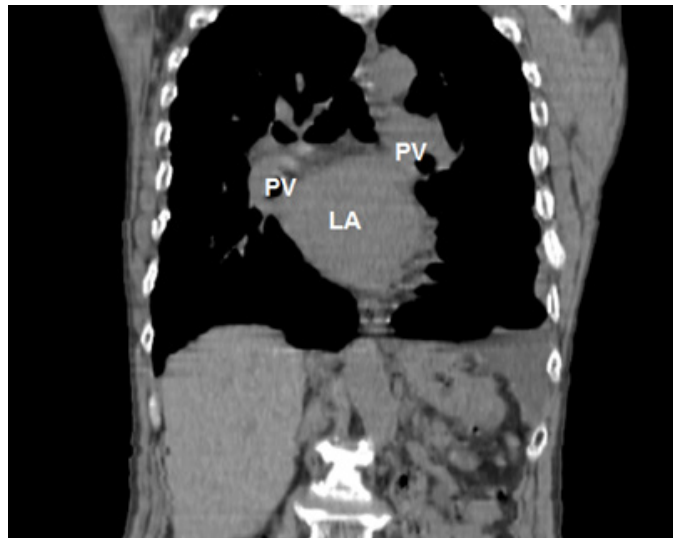
**Figure 6.16:** Computed tomography of the heart. Increased size of the left atrial appendage. It can be also visible on a chest X-ray at the level of the “gulf of the heart”.



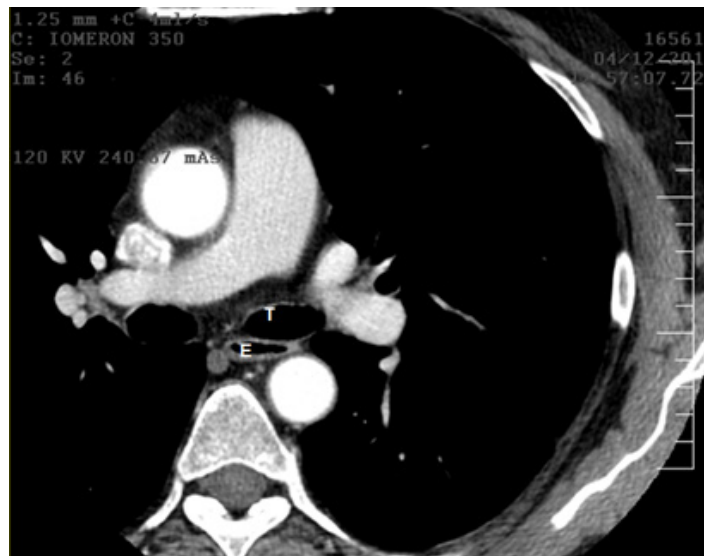**Figure 6.17:** Computed tomography of the heart. Increased dimensions of the left atrium.



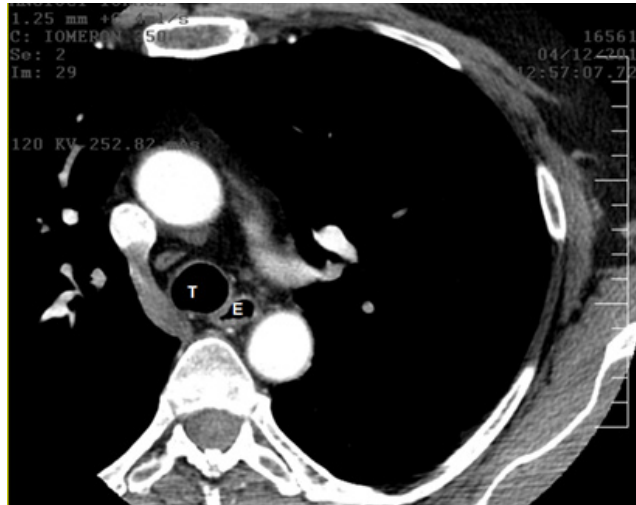
**Figure 6.18:** Computed tomography of the heart. The left atrium as it is seen from a lateral view.



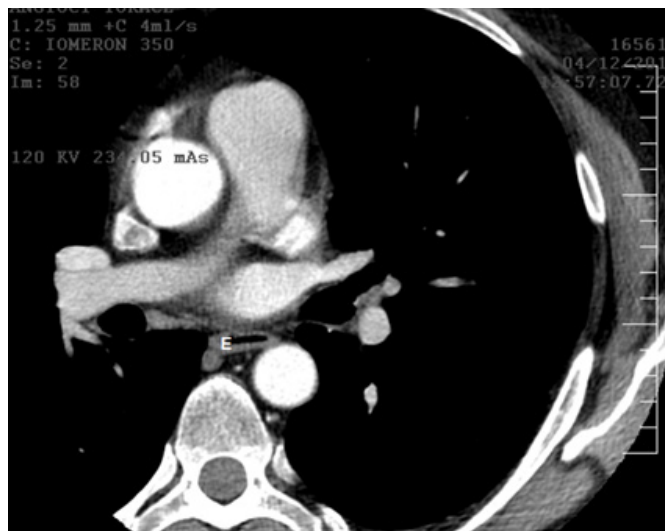**Figure 6.19:** Computed tomography of the heart. Left atrium with pulmonary veins is visible on a PA view.



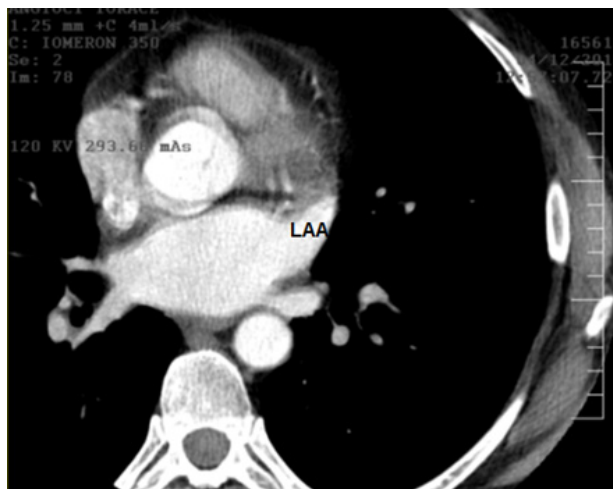
**Figure 6.20:** Computed tomography of the heart. The Esophagus and Trachea are posterior structures, being situated between the heart and the descending aorta. E=esophagus; T=trachea.



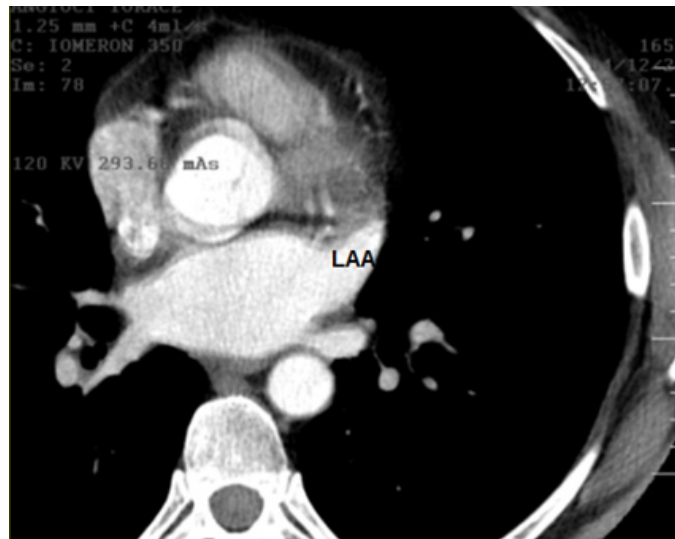
**Figure 6.21:** Computed tomography of the heart. The Esophagus and Trachea are posterior structures, being situated between the heart and the descending aorta. The image shows the Trachea before the bifurcation in 2 main bronchi.



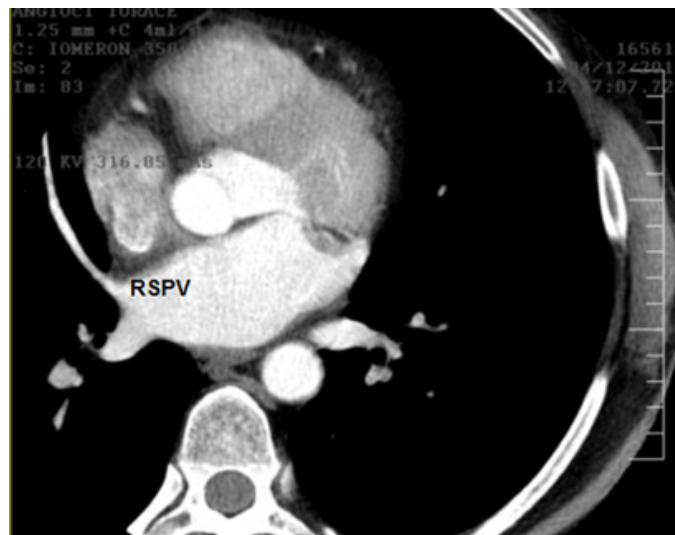
**Figure 6.22:** Computed tomography of the heart. The Esophagus is posterior structures, being situated between the heart and the descending aorta. In this image the esophagus is posterior o the left atrium, behind the right superior pulmonary vein.



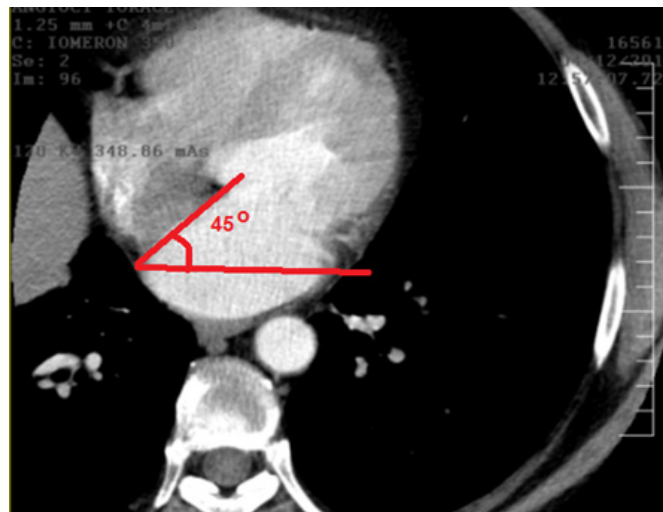**Figure 6.23:** Computed tomography of the heart. The left atrial appendage is an antero-lateral structure, very well represented in his image.



**Figure 6.24:** Computed tomography of the heart. In the same view the LAA and LSPV are visible, together with the RSPV. Veins that are found in the same plane with LAA are superior veins. LAA presents trabeculations inside it.

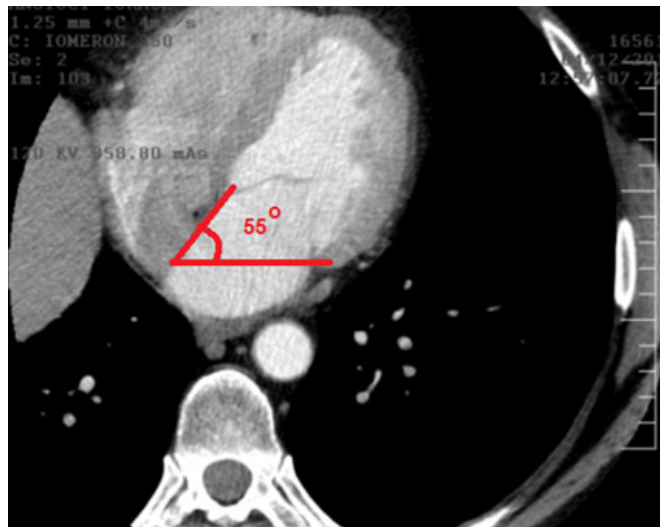


**Figure 6.25:** Computed tomography of the heart. A long branch of the RSPV is visible, heading towards the right pleura.

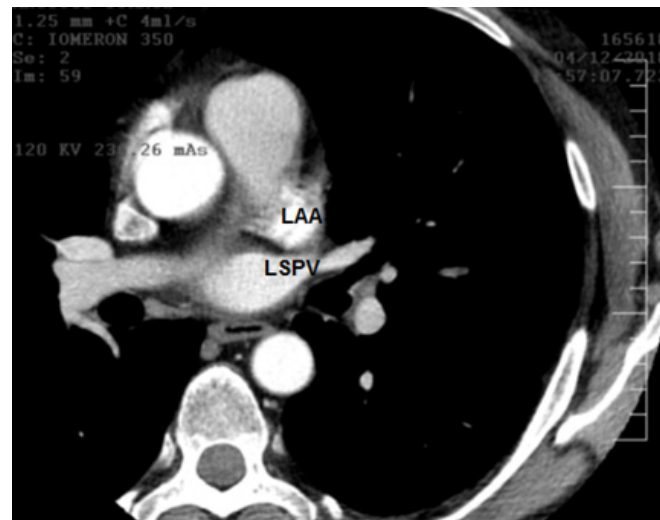


**Figure 6.26:** Computed tomography of the heart. Angle between the right atrium and the left atrium. It is useful for transeptal puncture.

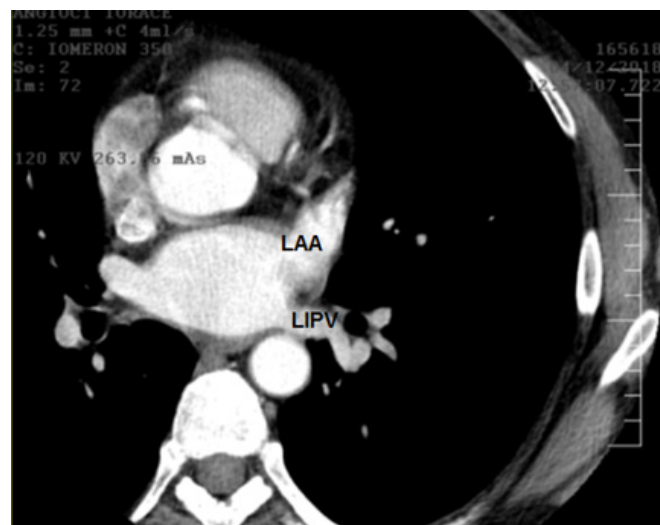




**Figure 6.27:** Computed tomography of the heart. Angle between the right atrium and the left atrium. It is useful for transeptal puncture.

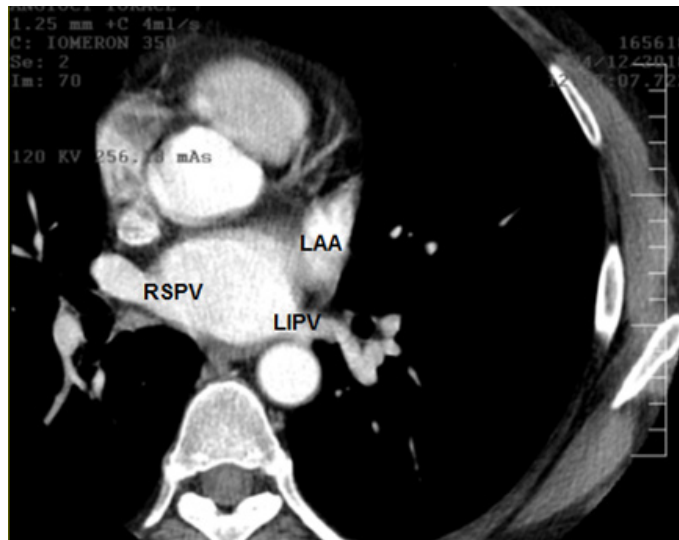


**Figure 6.28:** Computed tomography of the heart. Left atrial appendage and left superior pulmonary vein. LSPV has an anterior orientation.

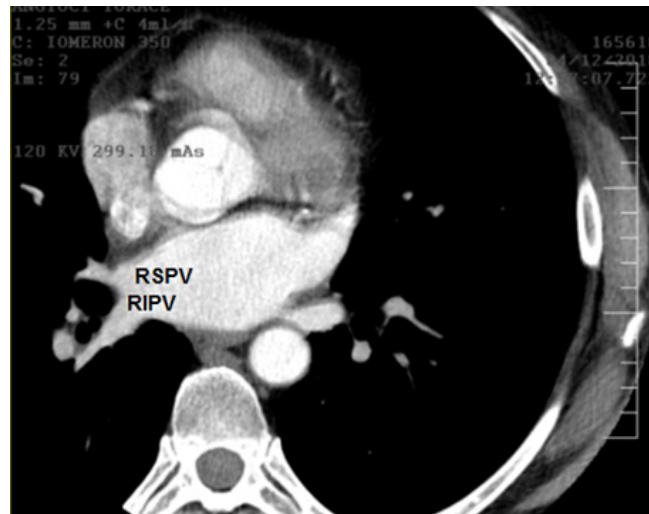


**Figure 6.29:** Computed tomography of the heart. Left atrial appendage and left inferior pulmonary vein. LIPV has a posterior orientation.

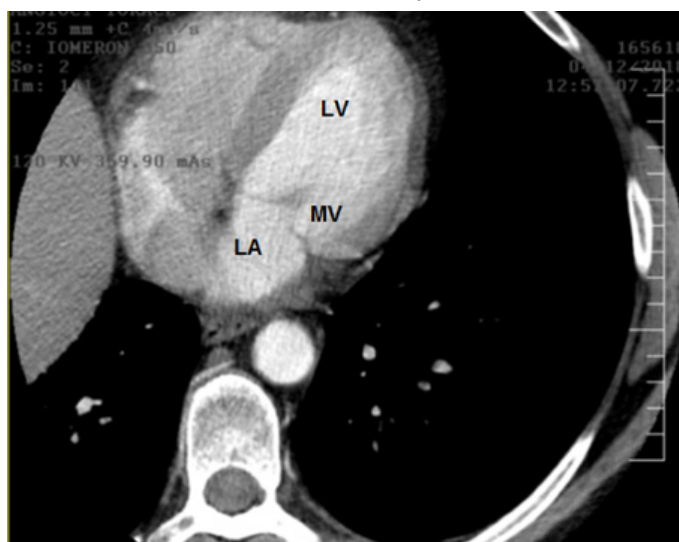




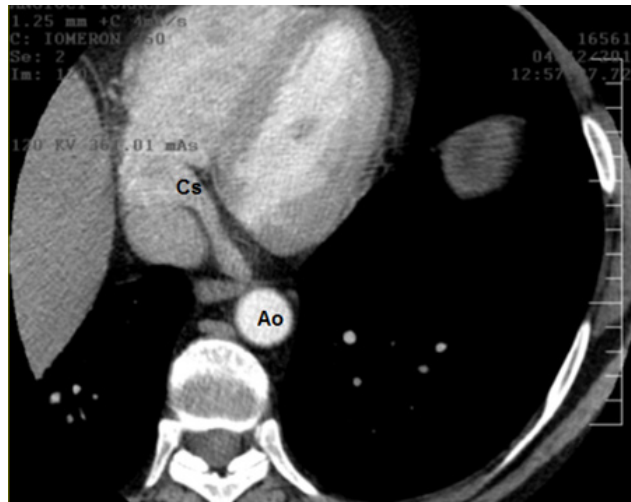
**Figure 6.30:** Computed tomography of the heart. Left atrial appendage, right superior pulmonary vein and left inferior pulmonary vein. LIPV has a posterior orientation and RSPV has an anterior orientation.



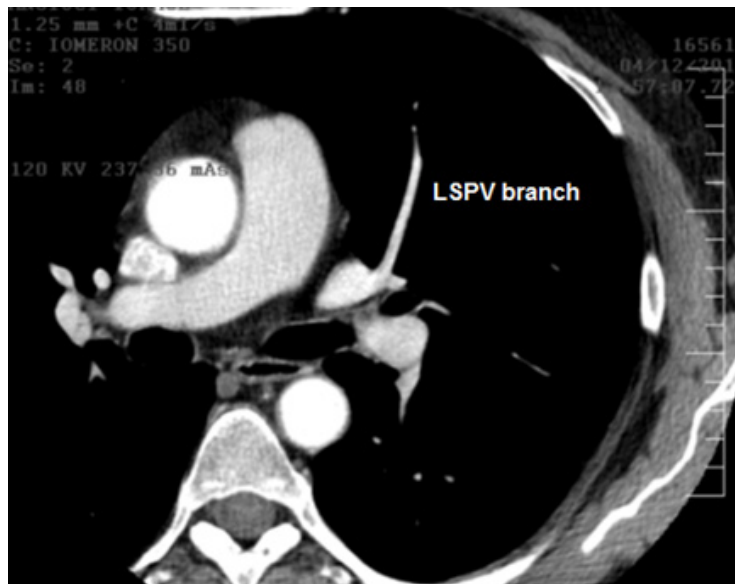
**Figure 6.31:** Computed tomography of the heart. Right veins can be differentiated by their orientation: RSPV has an anterior orientation, RIPV has a posterior orientation.



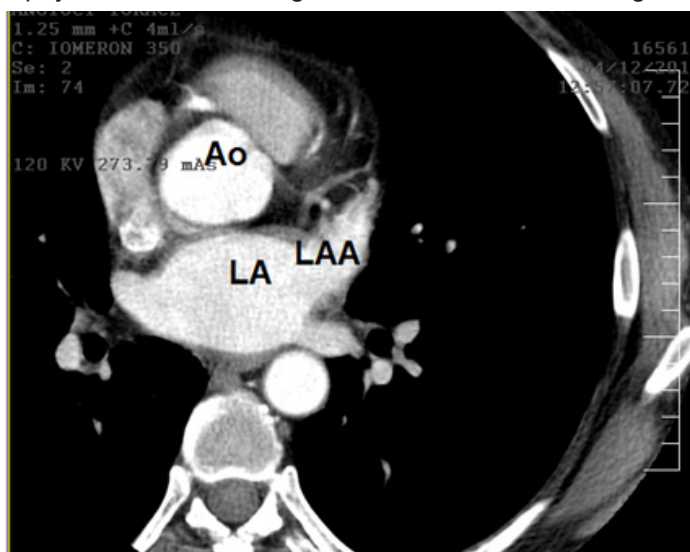
**Figure 6.32:** Computed tomography of the heart. Mitral valve is between the left ventricle and the left atrium.



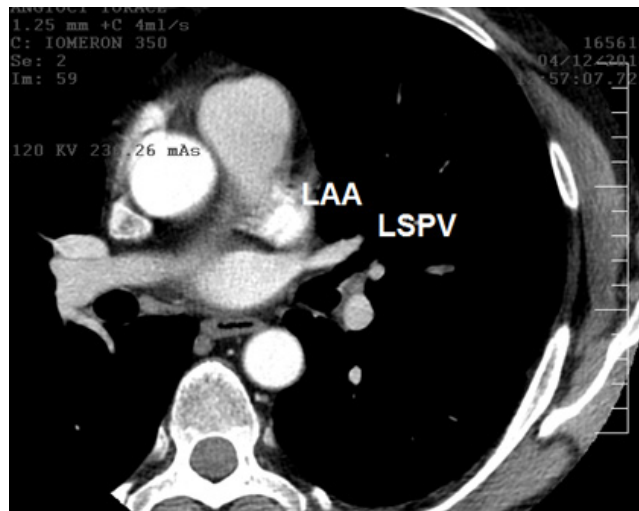
**Figure 6.33:** Computed tomography of the heart. The coronary sinus drains in the right atrium. Cs=coronary sinus; Ao=aorta.



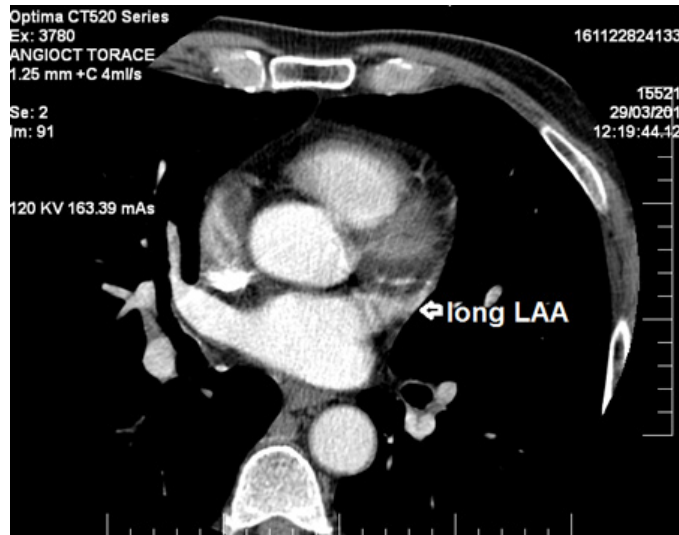
**Figure 6.34:** Computed tomography of the heart. A long branch of the LSPV heading to the left pleura can be visualized.



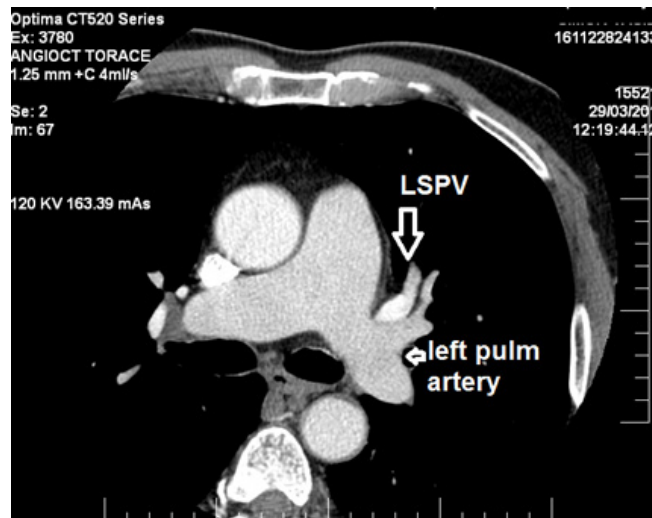
**Figure 6.35:** Computed tomography of the heart. The left atrial appendage is an anterior and lateral structure.



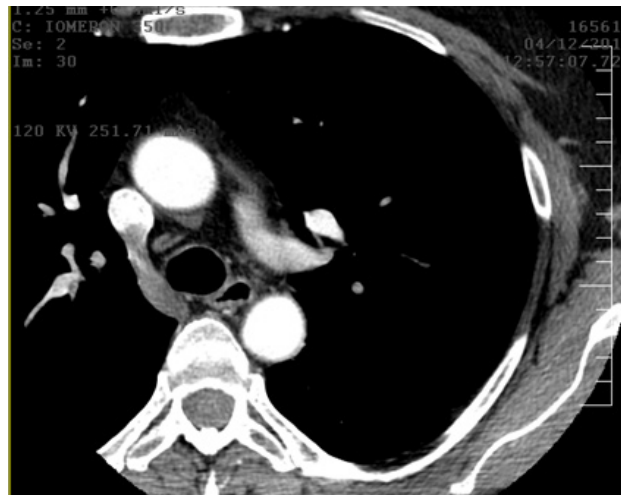**Figure 6.36:** Computed tomography of the heart. The vein that emerges in the same plane with the LAA is the LSPV. It has an anterior orientation.



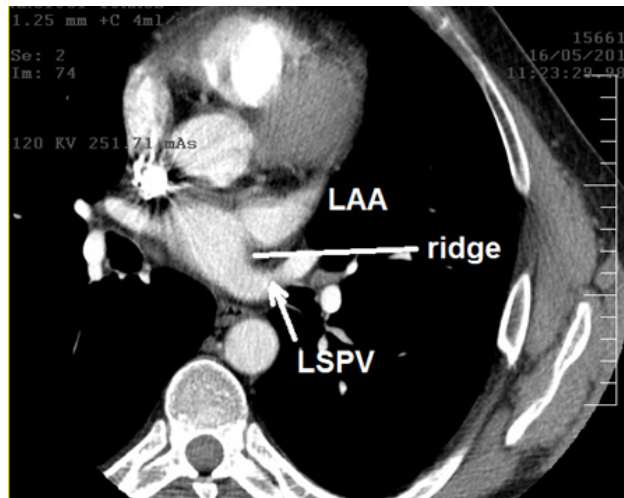
**Figure 6.37:** Computed tomography of the heart. Long atrial appendage is visible, with trabeculations inside it.



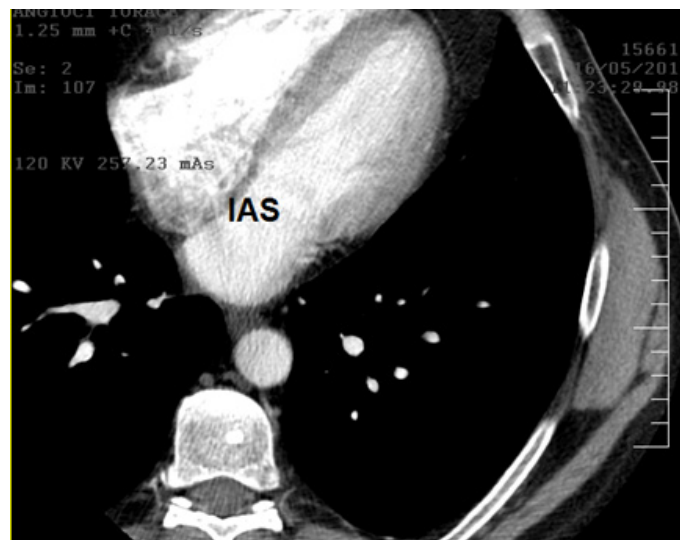**Figure 6.38:** Computed tomography of the heart. Relationship between the pulmonary artery and the pulmonary vein. LSPV and left pulmonary artery can be seen together and sometimes it is difficult to differentiate them. The density of the contrast substance.



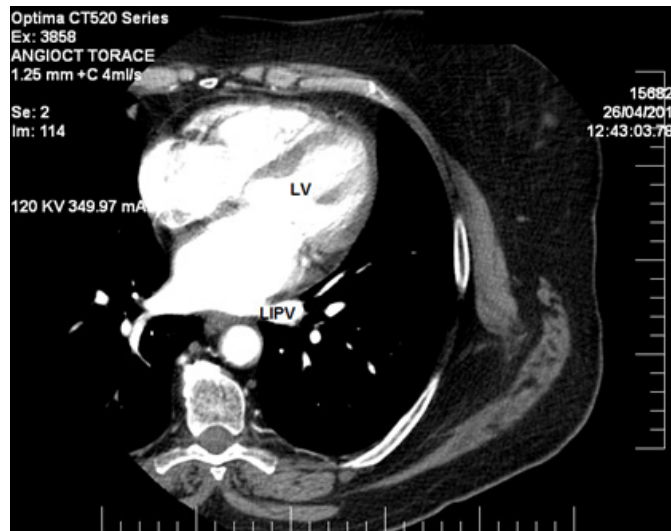**Figure 6.39:** Computed tomography of the heart. Both esophagus and trachea are visible in this image. They are posterior structures being localized between the heart and the descending aorta.



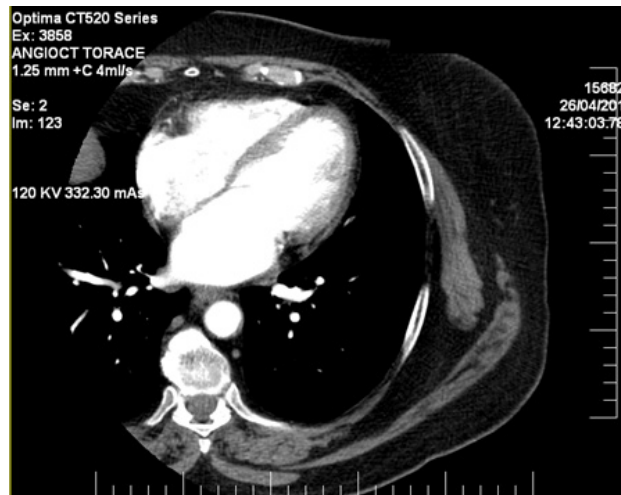
**Figure 6.40:** Computed tomography of the left atrium. In order to differentiate between LSPV and LIPV the left atrial appendage is searched. The vein that is seen in the same plan with LAA is the LSPV. The structure between LAA and LSPV is called the ridge, which is important for isolation of the LSPV.



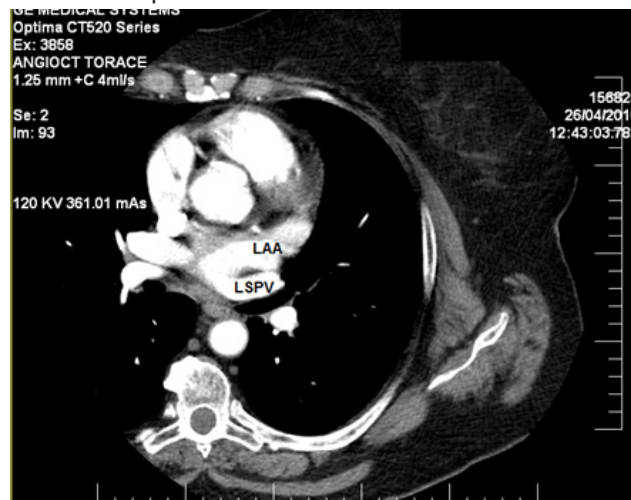
**Figure 6.41:** Computed tomography of the heart. Interatrial septum is a structure that can be found between the left atrium and right atrium. IAS orientation is important for transseptal puncture. The puncture should be performed in the fibroelastic zone of the IAS the so-called fossa ovalis.



**Figure 6.42:** Computed tomography of the left atrium. In order to differentiate between LSPV and LIPV the left atrial appendage or the left ventricle is searched. The vein that is seen in the same plan with LV is the LIPV.



**Figure 6.43:** Computed tomography of the heart. Both the right atrium and the left atrium can be seen. Between them the interatrial septum lies. The angle made by the interatrial septum with the horizontal line is approximately 45 degrees, therefore the transeptal needle should be oriented towards 16 o'clock.



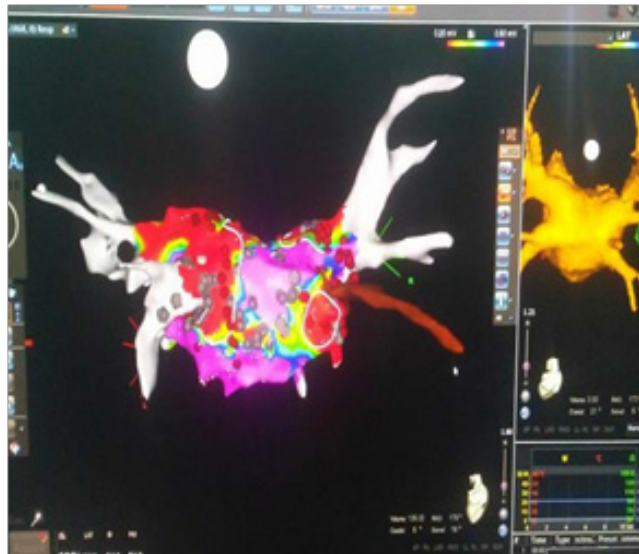
**Figure 6.44:** Computed tomography of the left atrium. In order to differentiate between LSPV and LIPV the left atrial appendage is searched. The vein that is seen in the same plan with LAA is the LSPV. The structure between LAA and LSPV is called the ridge, which is important for isolation of the LSPV.

# Chapter 7

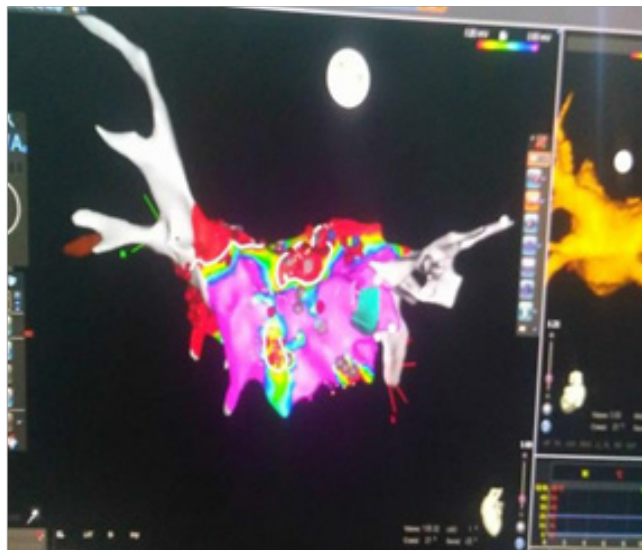


## Image Integration

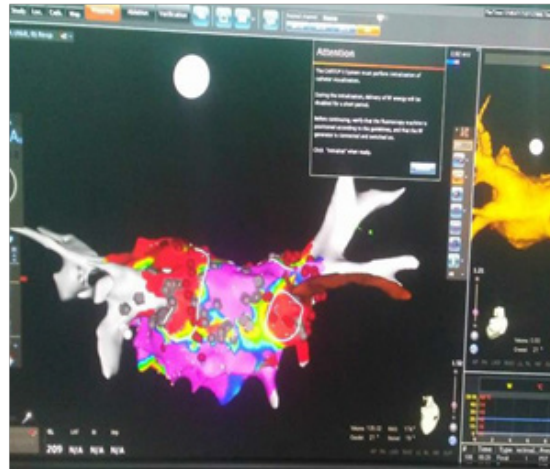
Preprocedural acquired CT can be merged with the electro anatomical map reconstructed with the aid of a 3-dimensional system (Carto-Biosense Webster, Ensite-Saint Jude or Rhythmia- Boston Scientific). Before the ablation, the cardiac CT is segmented into different structures and the left atrium selected for image integration. The obtained image permits to monitor the exact catheter position in relation with the venous ostia, superior or posterior wall or other endocardial borders. Complications like pulmonary vein stenosis and atrio-ventricular fistula can be avoided by using image integration. Limitations of the image integration consists in: time interval during CT performance and catheter ablation- during such a long period to time the position of the anatomical structures change, along with the fluid status [10]. Furthermore, breathing during electro anatomical mapping can affect acquisition of endocardial exact location [11,12] (Figure 7.1-7.48).



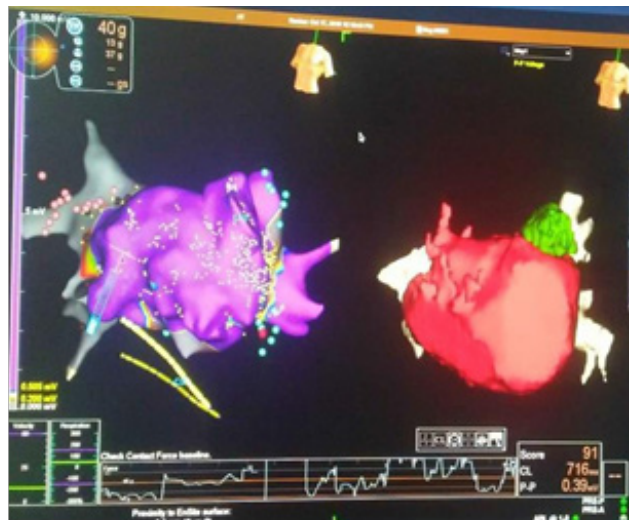
**Figure 7.1:** Image of the left atrium obtained with the image integration function of the Carto system. The voltage map shows parcelar areas of low voltage with significance of fibrosis. Posterior view.



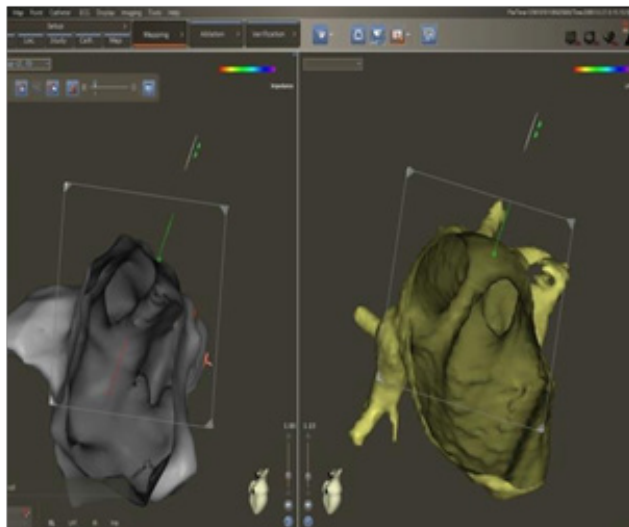
**Figure 7.2:** Same as in figure 7.1. Anterior view showing zones of fibrosis in red identified by a low voltage of atrial myocardium  $<0.2V$ .



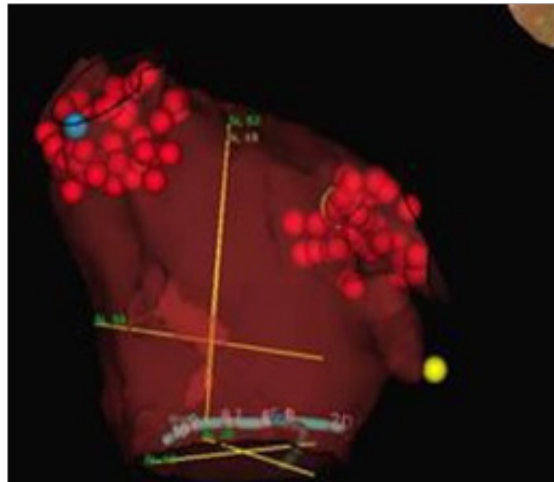
**Figure 7.3:** Computed tomography of the heart. Both esophagus and trachea are visible in this image. They are posterior structures being localized between the heart and the descending aorta.



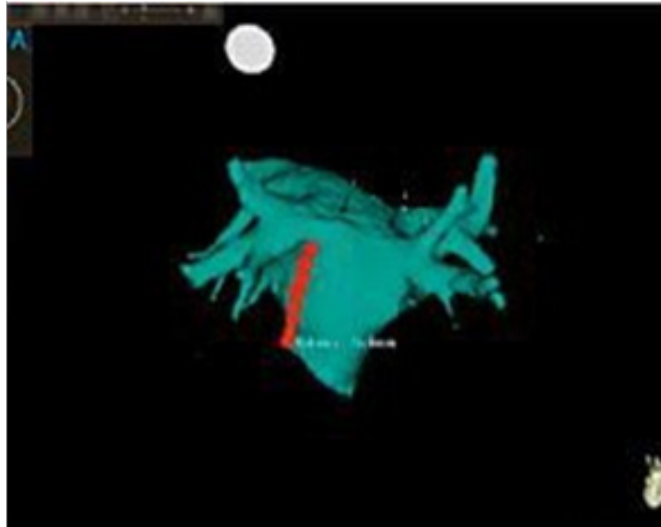
**Figure 7.4:** Image obtained using the image integration soft of the NAVX system-Ensite Velocity Saint Jude. On the left side the electroanatomical map of the left atrium shows absence of low voltage zones; on the right side the anatomy of the left atrium as seen in computer tomography.



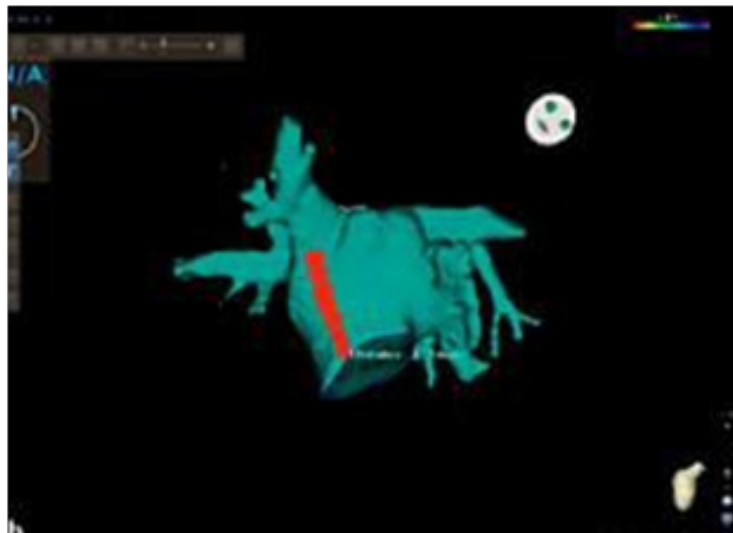**Figure 7.5:** Merge between the electroanatomical map (left side) and computed tomography (right side). Images are very similar in terms of anatomy of left veins and ridge between the veins.



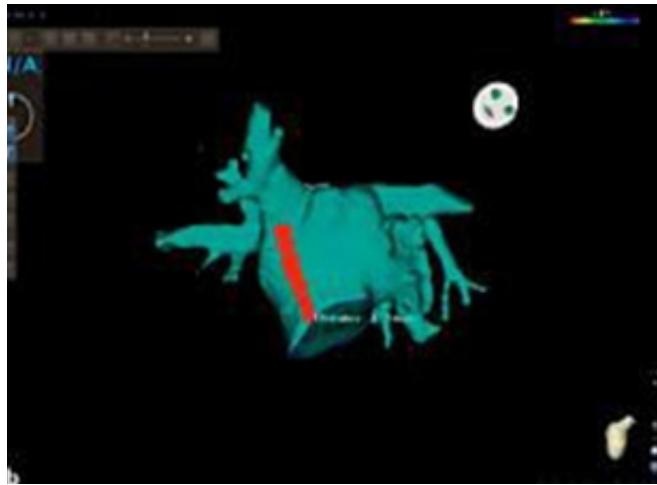
**Figure 7.6:** Measurement of the diameters of the left atrium after isolation of pulmonary veins. Three diameters are measured: latero-lateral, antero-posterior and supero-inferior.



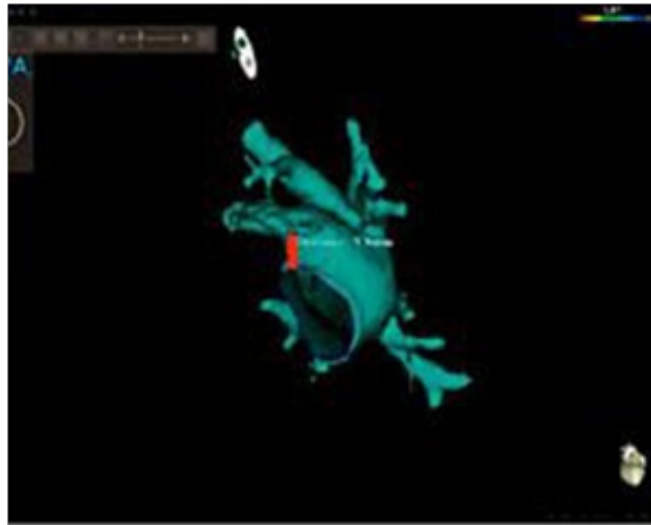
**Figure 7.7:** Distance between left inferior pulmonary vein and mitral annulus as measured in computer tomography. (adapted from reference [10]).



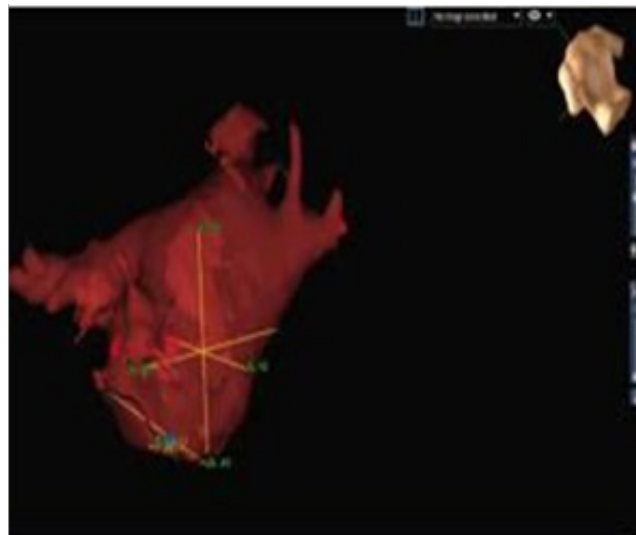
**Figure 7.8:** Distance between right superior pulmonary veins and mitral annulus as measured in computed tomography. (adapted from reference [10]).



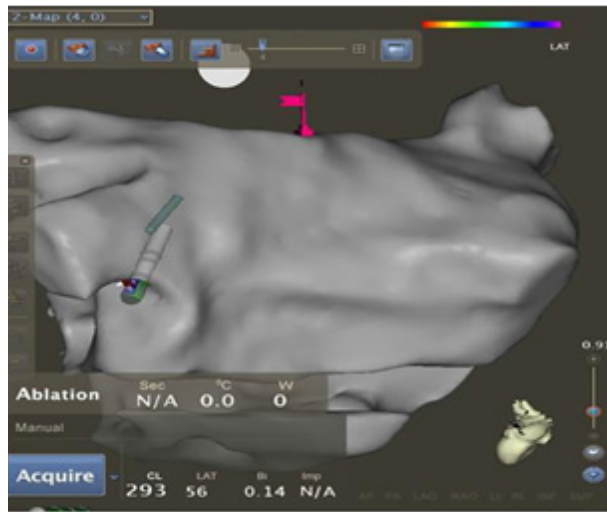
**Figure 7.9:** Computed tomography of the heart integrated with the 3 D system. Distance between RIPV and mitral annulus. (adapted from reference [10]).



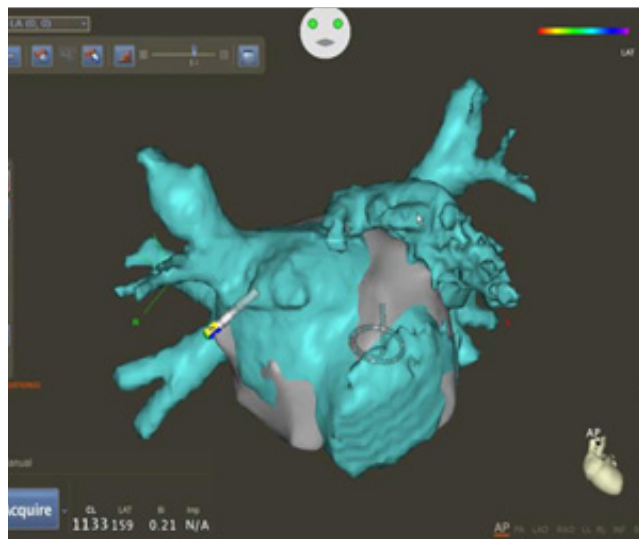
**Figure 7.10:** Computed tomography of the heart. integrated with the Carto 3 system. Distance between LAA and mitral annulus. (adapted from reference [10]).



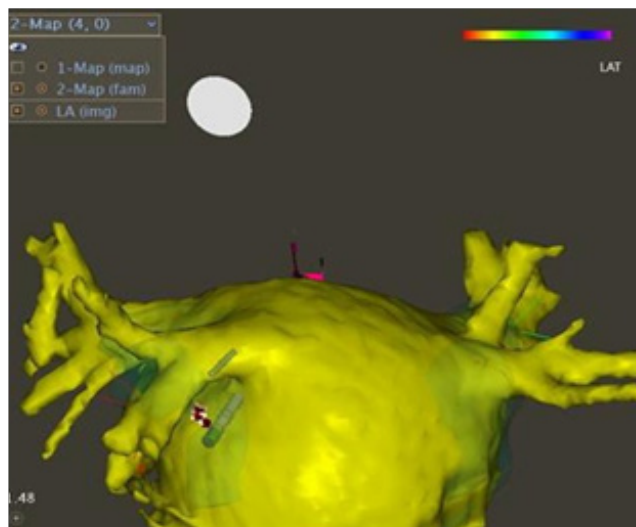
**Figure 7.11:** Computed tomography of the left atrium before catheter ablation. Three diameters of the LA are measured: antero-posterior, latero-lateral and supero-inferior.



**Figure 7.12:** Electroanatomical map of the left atrium. This image was obtained with the ablation catheter while moved inside the pulmonary veins and left atrium.

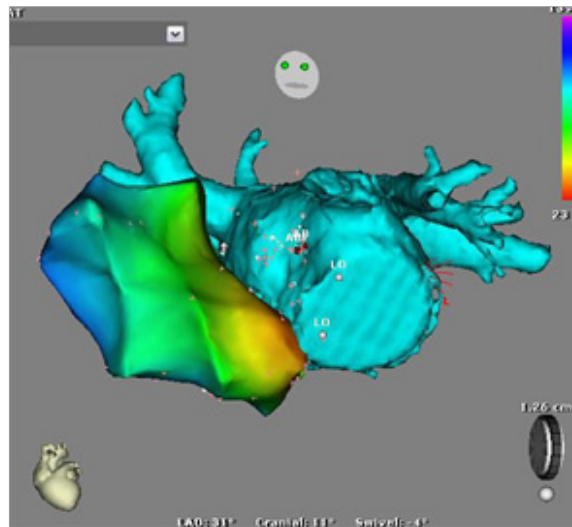


**Figure 7.13:** Merge between compute tomography of left atrium and anatomical map of left atrium.

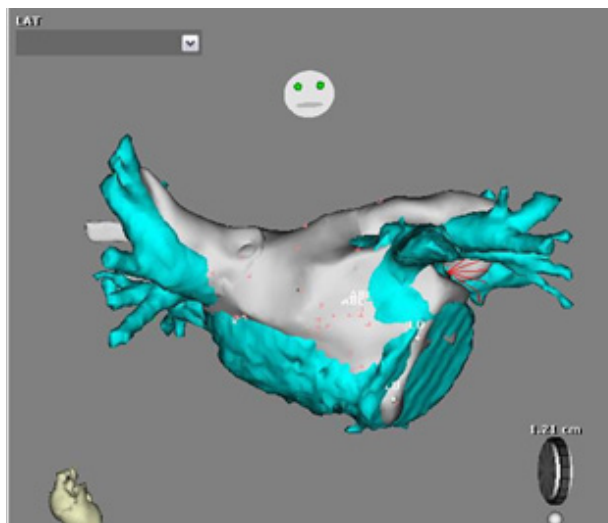


**Figure 7.14:** After merging the computed tomography with the electroanatomical map, catheter ablation can be performed using only the CT image.

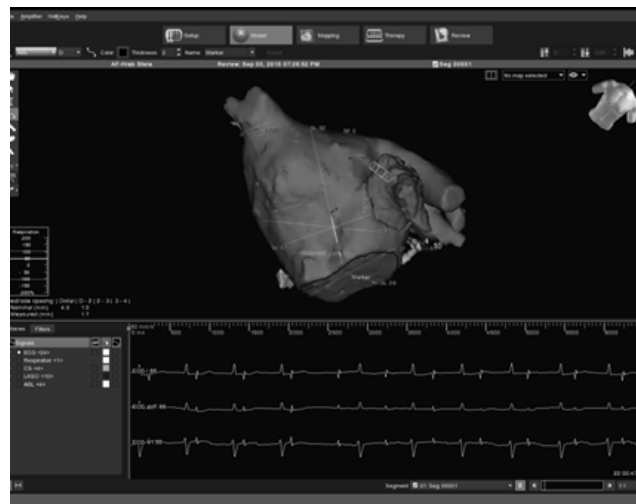




**Figure 7.15:** Computed tomography of the left atrium and electroanatomical reconstruction of the right atrium with activation of the right atrium during tachycardia.

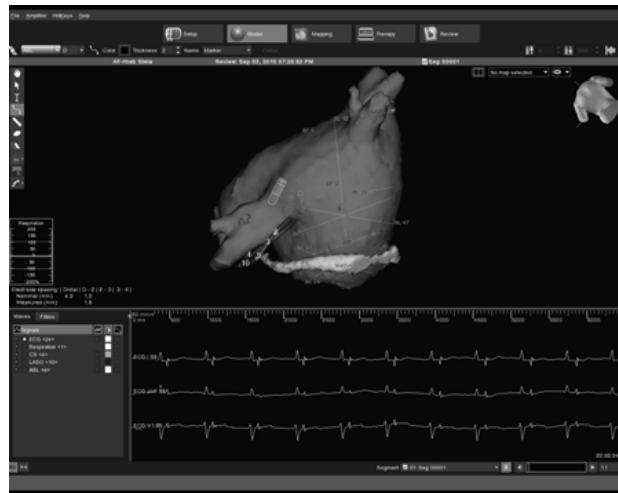


**Figure 7.16:** Electroanatomical reconstruction of the four pulmonary veins and left atrium. The electroanatomical map is fused with the computed tomography of the LA.

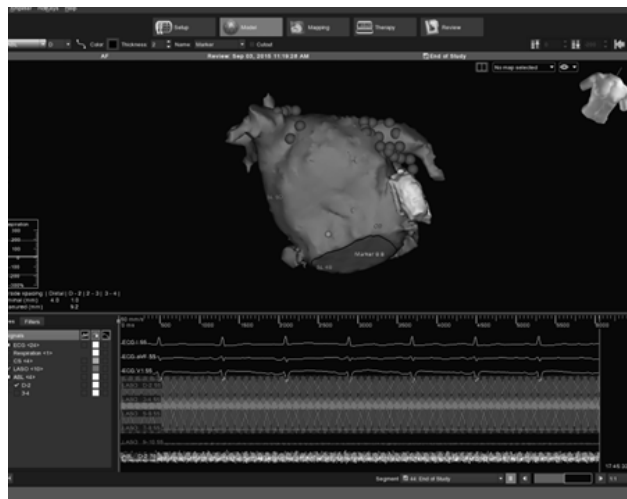


**Figure 7.17:** Image integration. Computed tomography was integrated with the Carto 3 system. Three diameters of the left atrium were measured: latero-lateral, antero-posterior and supero-inferior. With white color the coronary sinus can be visualized. The atrial appendage is an anterior structure that comes close to the anterior mitral ring.

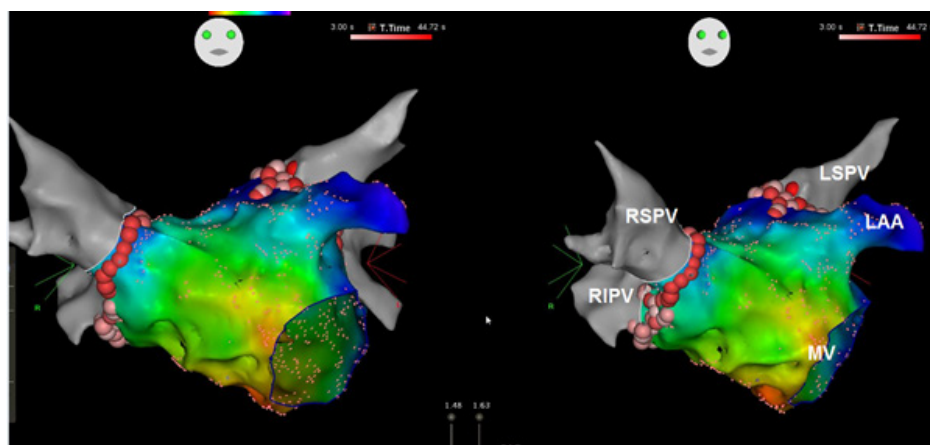




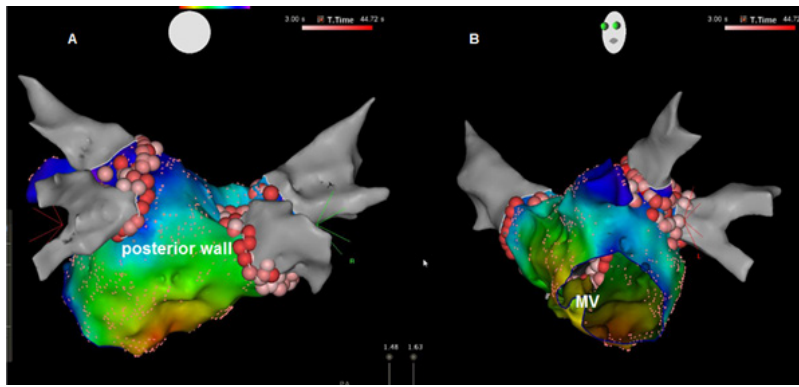
**Figure 7.18:** Image integration. Computed tomography was integrated with the Carto 3 system. Three diameters of the left atrium were measured: latero-lateral, antero-posterior and supero-inferior. With white color the coronary sinus can be visualized.



**Figure 7.19:** Image integration. Computed tomography was integrated with the Carto 3 system and catheter ablation was performed on this image. Bullets are RF point placed at the ostium of the pulmonary veins. With white color the left atrial appendage can be visualized, coming close to the mitral ring and coronary sinus.

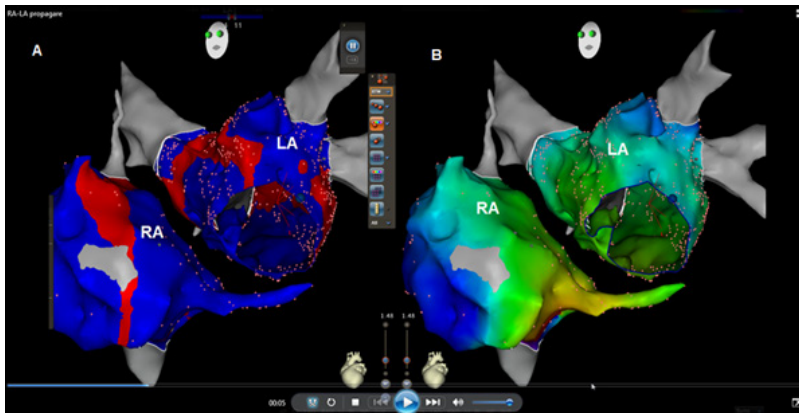


**Figure 7.20:** Activation map of a left atrial tachycardia. Anterior view. The focus of the tachycardia is localized on the inferior part of the posterior wall (red color). From this spot the left atrium is electrically activated, the last portion being the left veins (blue color). Please note that the 4 pulmonary veins are electrically isolated by ablation (red and pink dots). RSPV=right superior pulmonary vein. RIPV=right inferior pulmonary vein. LSPV=right superior pulmonary vein; LIPV=right inferior pulmonary vein. LAA=left atrial appendage. MV=mitral valve.



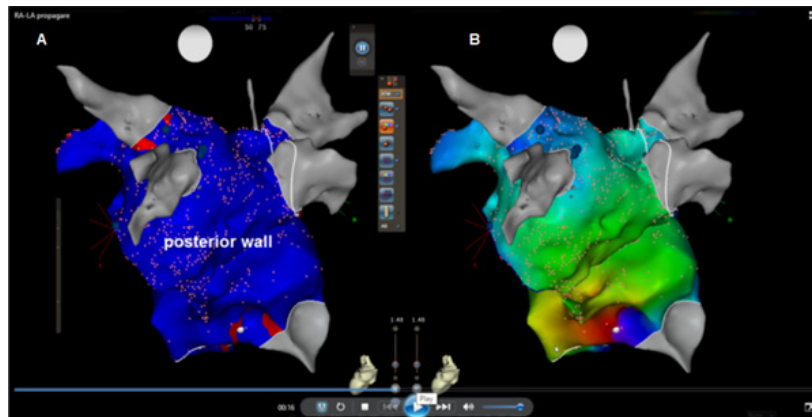
**Figure 7.21:** CActivation map of a left atrial tachycardia. The focus of the tachycardia is localized on the inferior part of the posterior wall (red color). From this spot the left atrium is electrically activated, the last portion being the left veins (blue color). Please note that the 4 pulmonary veins are electrically isolated by ablation (red and pink dots)

- A. Posterior view.
- B. Anterior view.



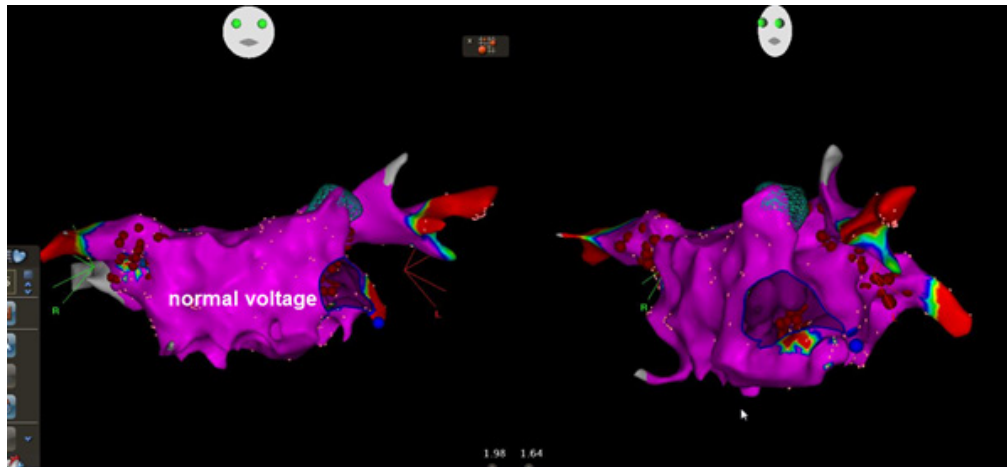
**Figure 7.22:** Propagation map and activation map from a right atrial focal tachycardia.

- A. Electroanatomical map of the right and left atrium with propagation of the electrical activation from the focus to the entire right and left atrium.
- B. Activation map shows a focus of the right atrium (red color) that propagates to the entire right atrium and then to the left atrium.

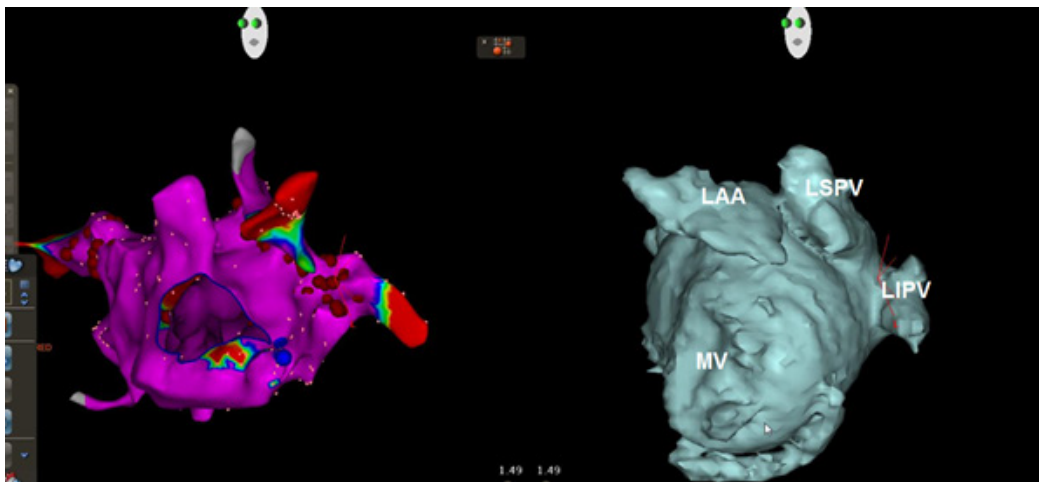


**Figure 7.23:** Propagation map and activation map of a right atrial focal tachycardia.

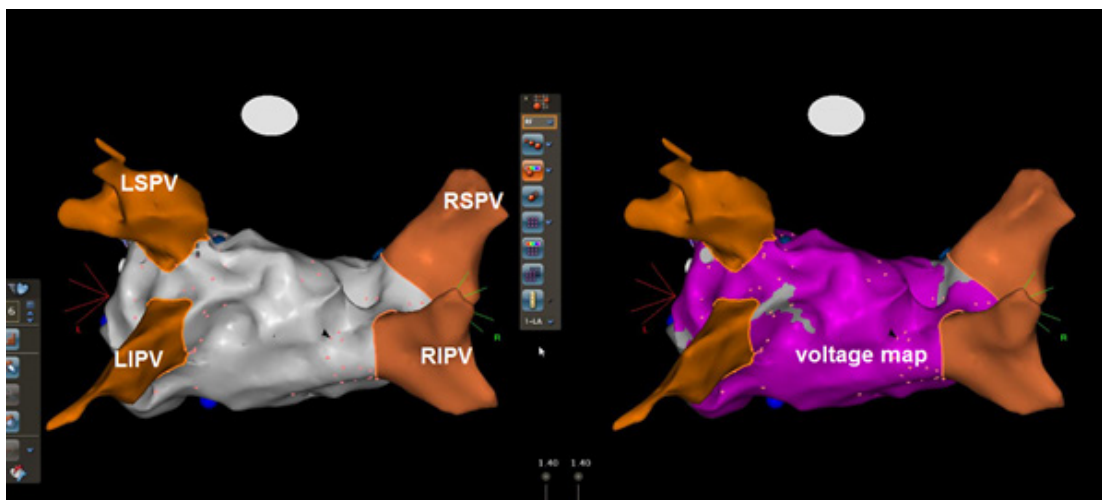
- A. Electroanatomical map of the right and left atrium with propagation of the electrical activation from the focus to the entire right and left atrium.
- B. Activation map shows a focus of the right atrium (red color) that propagates to the right atrium and then to the left atrium.



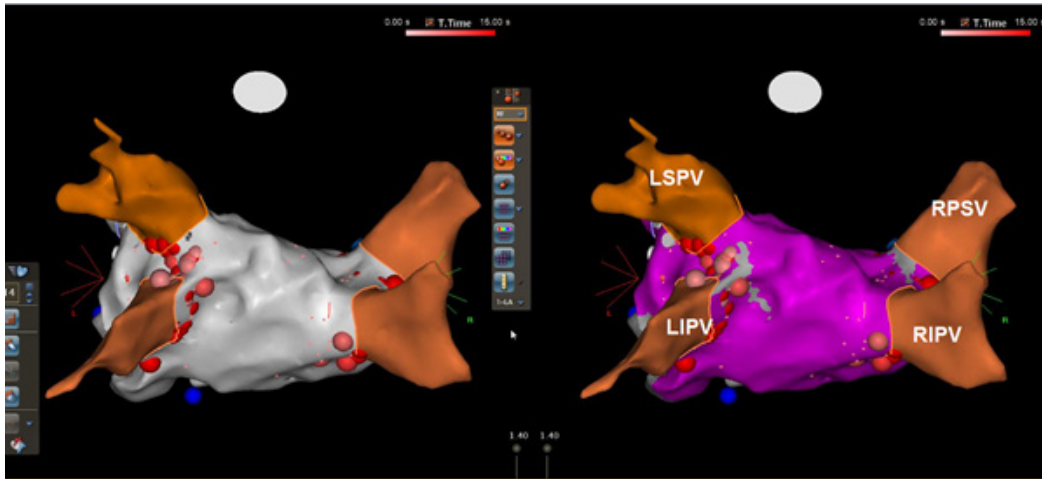
**Figure 7.24:** Electroanatomical map of the left atrium. Voltage map shows purple color in case of normal atrial tissue and red color in case of scar. In this image the left atrium has a normal voltage.



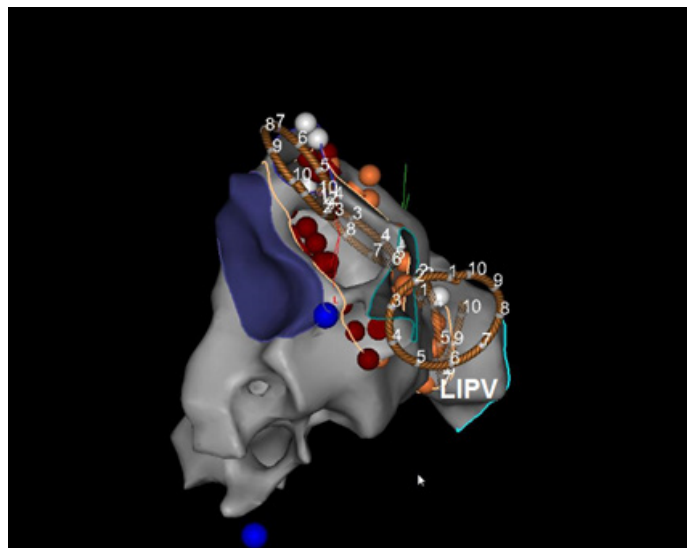
**Figure 7.25:** Image integration. Correspondence between electroanatomical map and computer tomography. The first image shows an electroanatomical map of the left atrium with a normal voltage map without atrial areas of scar; the second image shows the CT of the same patient with the same anatomical landmarks as the first map. LAA= left atrial appendage, LSPV=left superior pulmonary vein; LIPV=left inferior pulmonary vein, MV=mitral valve.



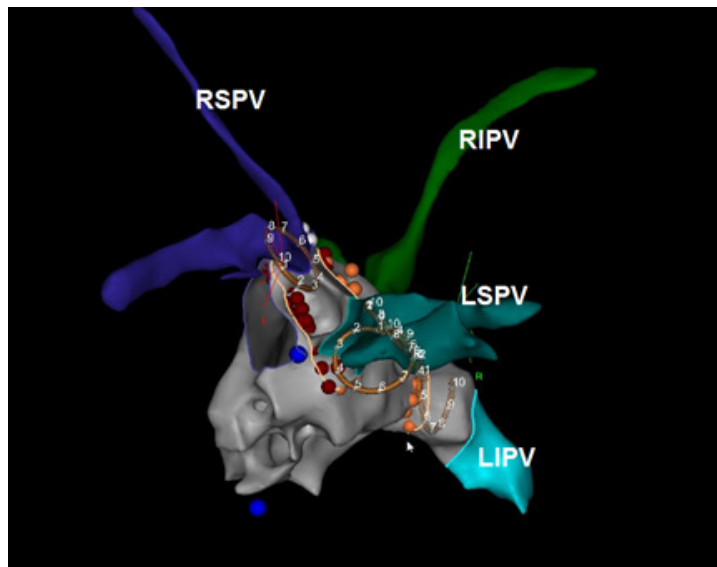
**Figure 7.26:** Electroanatomical map and voltage map in the same patient. The first image shows electroanatomical map of a left atrium with 4 pulmonary veins. The second map shows a voltage map with the purple color being healthy atrial tissue, without any scar. LSPV=left superior pulmonary vein; LIPV=left inferior pulmonary vein; RSPV=right superior pulmonary vein; RIPV=right inferior pulmonary vein.



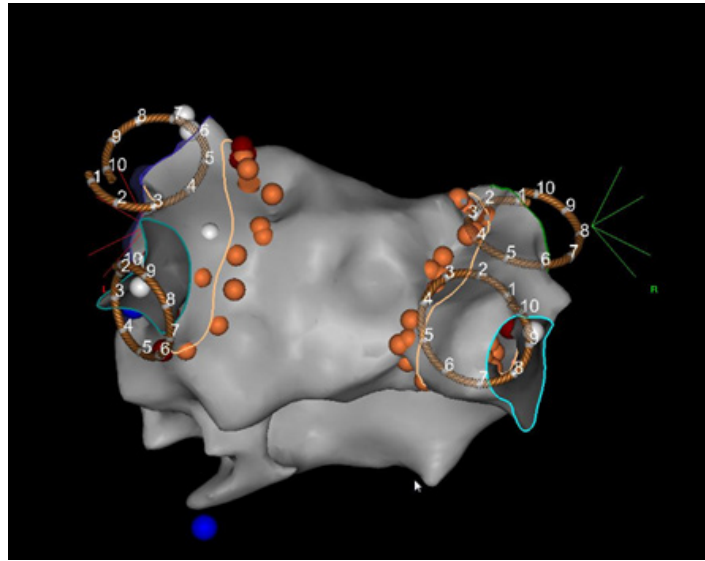
**Figure 7.27:** Image integration. Electroanatomical map of the left atrium. Red dots are points of RF applications at the level of the antrum of the four veins. LSPV=left superior pulmonary vein; LIPV=left inferior pulmonary vein; RSPV=right superior pulmonary vein; RIPV=right inferior pulmonary vein.



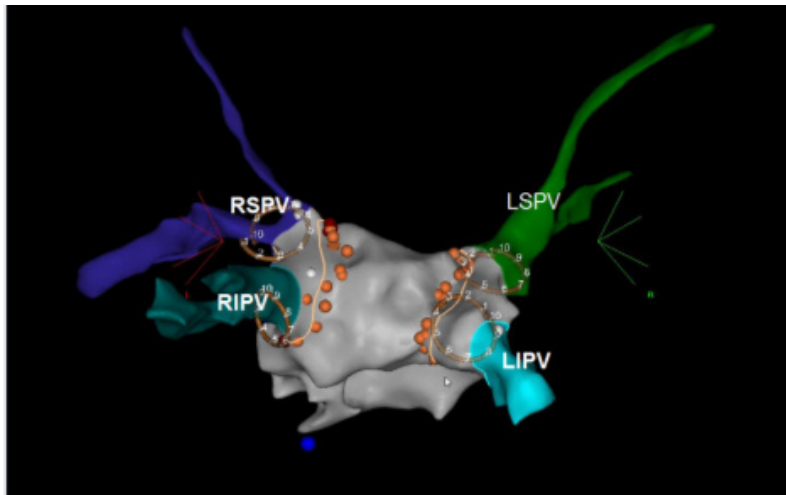
**Figure 7.28:** Electroanatomical map. Lasso catheter in a left inferior pulmonary vein.



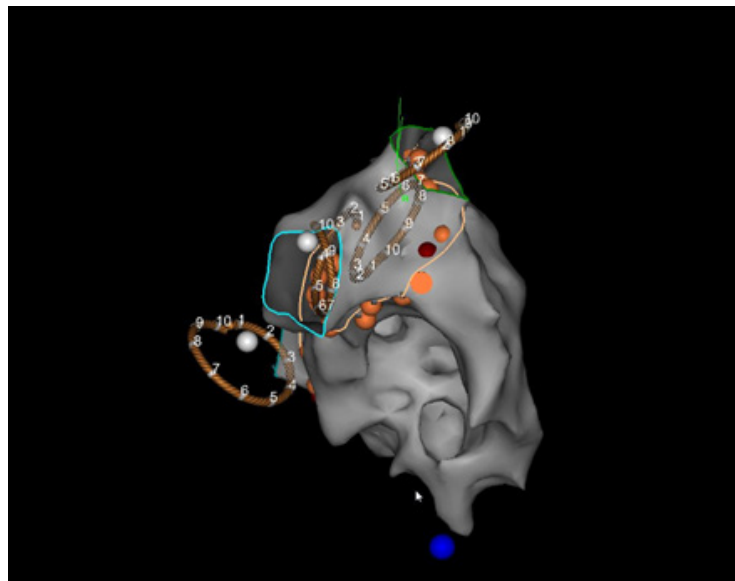
**Figure 7.29:** Electroanatomical map. Lasso catheter in the left superior pulmonary vein.



**Figure 7.30:** Electroanatomical map. Position of the Lasso catheter at the entrance (antrum) of the four pulmonary veins.



**Figure 7.31:** Electroanatomical map. RF Ablation points around the pulmonary veins. They were encircled 2 by 2.



**Figure 7.32:** Electroanatomical map. Lasso catheter inside the LIPV.



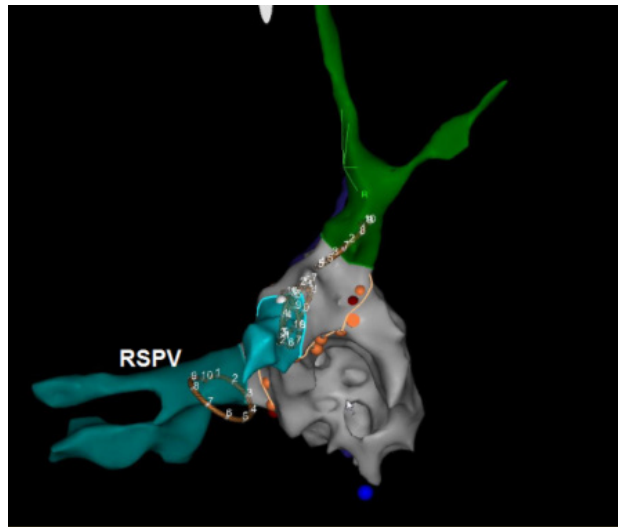


Figure 7.33: Image integration. Electroanatomical map. Lasso catheter inside the RSPV.

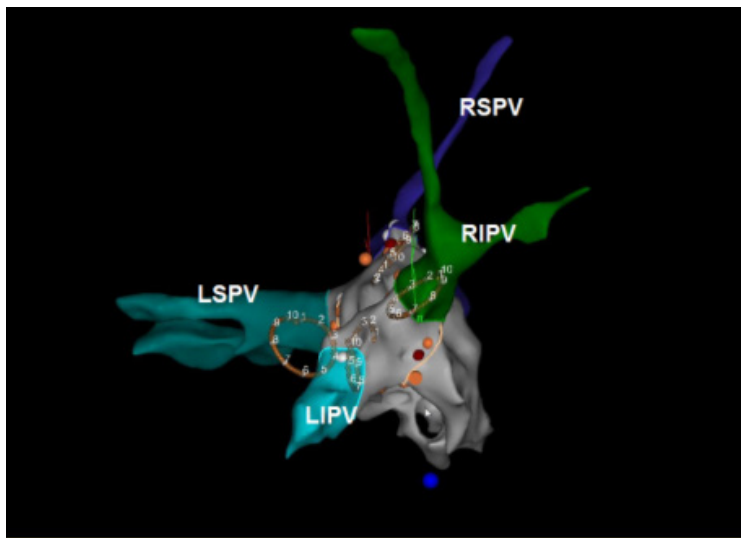


Figure 7.34: CImage integration. Electroanatomical map. Posterior view. Lasso catheter at the base of the four pulmonary veins.

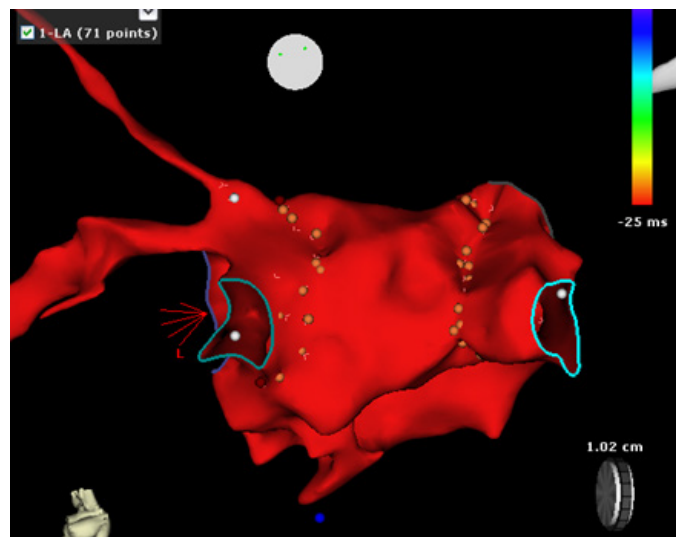
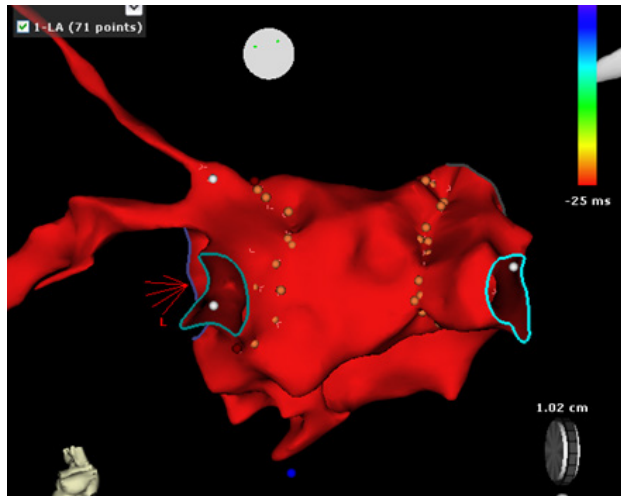
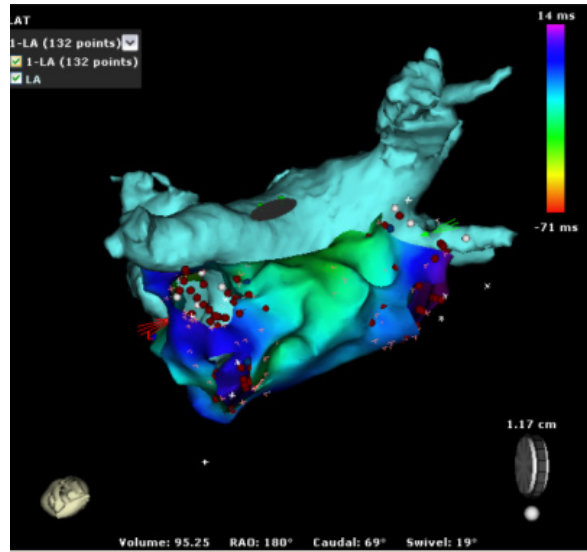


Figure 7.34: Image integration. Posterior view of an electroanatomical map of the left atrium. The LSPV can be visualized; the other 3 pulmonary veins are cut from the ostia.

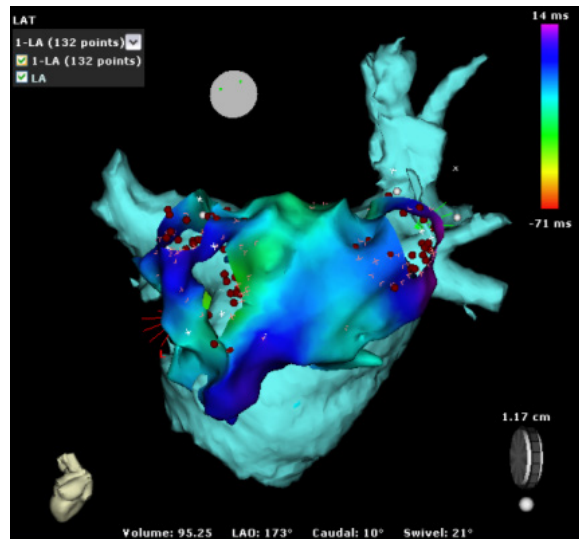




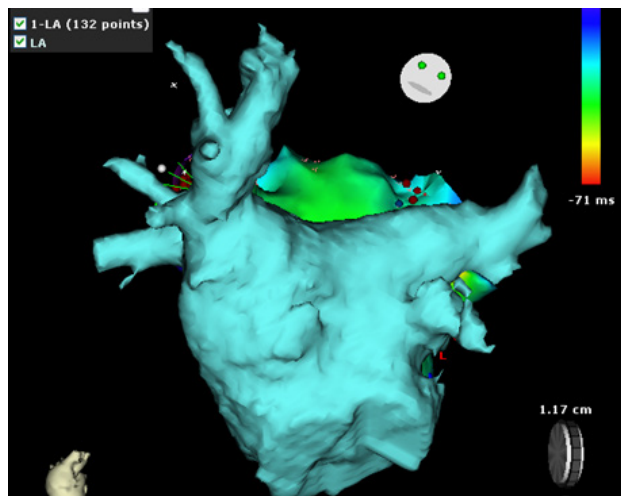
**Figure 7.35:** Image integration. Posterior view of an electroanatomical map of the left atrium. The LSPV can be visualized; the other 3 pulmonary veins are cut from the ostia.



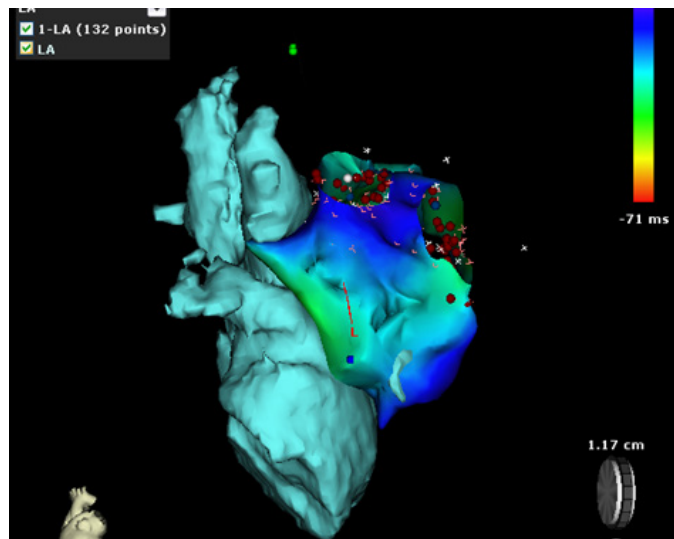
**Figure 7.36:** Image integration. Fusion between computed tomography of the left atrium and electroanatomical mapping. Superior view.



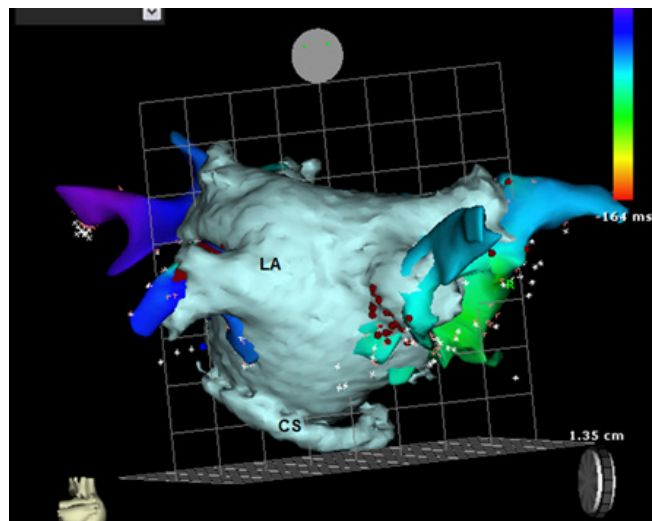
**Figure 7.37:** Image integration. Excellent fusion between computed tomography of the left atrium and electroanatomical mapping. Posterior view.



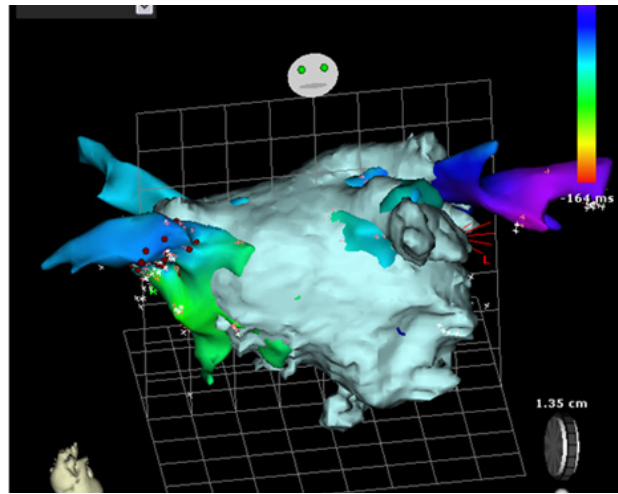
**Figure 7.38:** Image integration. Excellent fusion between computed tomography of the left atrium and electroanatomical mapping. Anterior view.



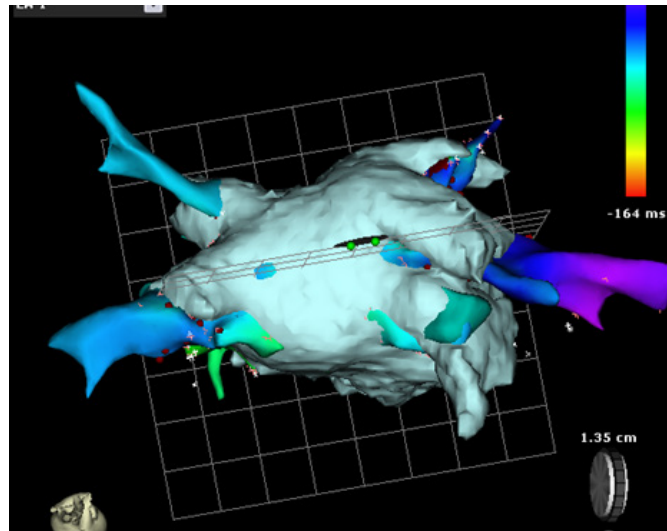
**Figure 7.39:** Image integration. Excellent fusion between computed tomography of the left atrium and electroanatomical mapping. Lateral view.



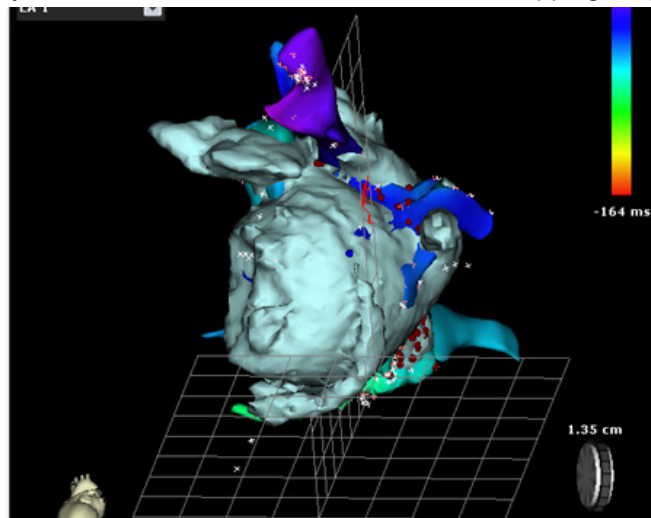
**Figure 7.40:** Image integration. Excellent fusion between computed tomography of the left atrium and electroanatomical mapping. Posterior view. In the inferior part of the image the coronary sinus can be viewed. LA=left atrium, CS=coronary sinus.



**Figure 7.41:** Image integration with the Carto system-Biosense Webster. Excellent fusion between computed tomography of the left atrium and electroanatomical mapping. Anterior view.



**Figure 7.42:** Image integration with the Carto system from Biosense Webster. Excellent fusion between computed tomography of the left atrium and electroanatomical mapping. Superior view.



**Figure 7.43:** Image integration with the Carto system from Biosense Webster. Excellent fusion between computed tomography of the left atrium and electroanatomical mapping. Left lateral view.

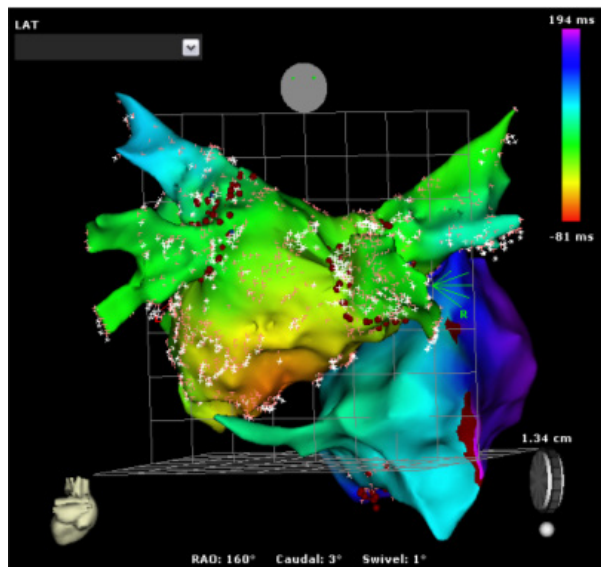


Figure 7.44: Image integration. Electroanatomical map of both the left atrium and right atrium. Anterior view.

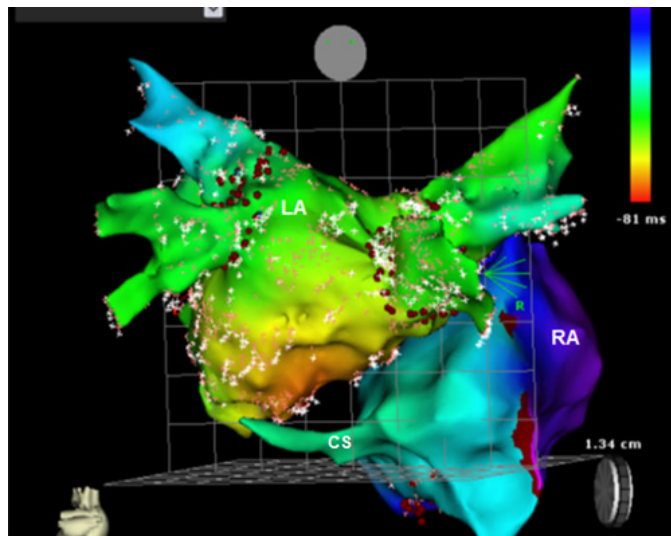


Figure 7.45: Image integration. Electroanatomical map of both the left atrium and right atrium. Posterior view. RA=right atrium; LA=left atrium; CS=coronary sinus.

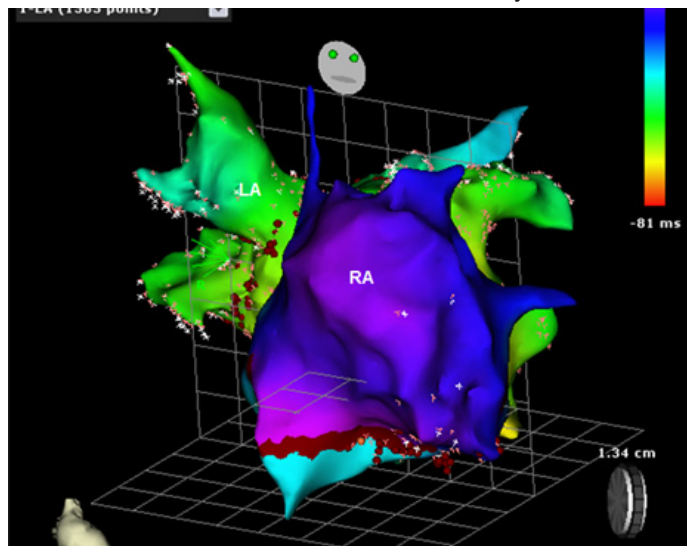
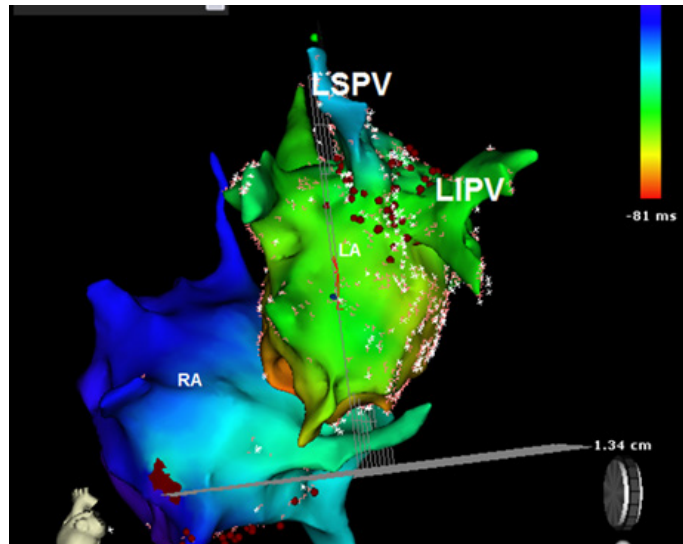
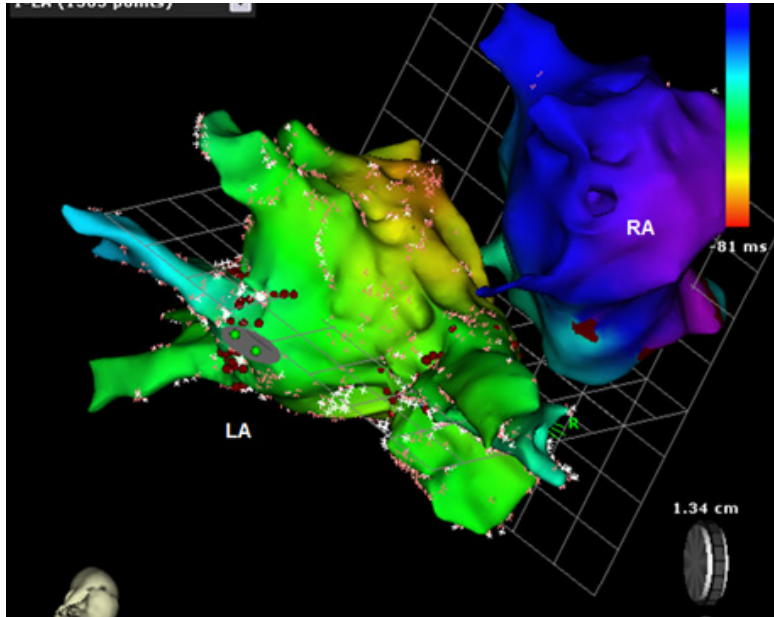


Figure 7.46: Image integration. Electroanatomical map of both the left atrium and right atrium. Right lateral view. LA=left atrium; RA=right atrium.



**Figure 7.47:** Image integration. Electroanatomical map of both the left atrium and right atrium. Right lateral view. LA=left atrium; RA=right atrium.



**Figure 7.48:** Image integration. Electroanatomical map of both the left atrium and right atrium. Right lateral view. LA=left atrium; RA=right atrium.

## Conclusion

Evaluation of the left atrium can be made by using several imaging modalities, each of which with specific indications, advantages and disadvantages.

a) Chest X-ray can be used as initial imaging tool for left atrial assessment and is particularly useful in cases of left atrial dilation. Although Chest X-ray is a widely available tool that involves a small dose of radiation, the resolution of the left atrium is low and interpretation of the left atrial dilation requires training and experience.

b) Echocardiography is the first-line examination for the dimension of the left atrium: diameters, area and volume. Pulmonary veins are difficult to differentiate as well as the left atrial appendage. Transesophageal



echocardiography is especially used to exclude left atrial and left atrial appendage thrombi, a finding that leads to absolute contraindication of electrical cardioversion or catheter ablation of atrial fibrillation.

c) Magnetic resonance imaging can be used in patients with congenital cardiopathies affecting the left atrium and pulmonary veins and is an alternative to computed tomography for patients that need catheter ablation of atrial fibrillation. The main advantage of Cardiac MRI is that it does not expose patients to ionizing radiation. On the other hand, It has a long duration of acquisition and is impossible to perform in patients with claustrophobia or those unable to cooperate with the doctor and medical staff.

d) Multidetector computed tomography is suitable for evaluation of pulmonary veins and left atrium before catheter ablation of atrial fibrillation. It has the advantage of a short examination time and high anatomical resolution with drawbacks of elevated radiation exposure and side effects of intravenous contrast injection: allergic reactions and renal impairment.

e) Much can be learned from the left atrium and pulmonary veins. Careful radiological and ultrasonographical examination of these structures can be used to

- i. distinguish between a normal left atrium and a dilated one;
- ii. recognize anomalies of number and shape of the pulmonary veins;
- iii. provide useful information on the venous antrum necessary for catheter ablation of atrial fibrillation or closure of the left.

## References

1. Cronin P, Sneider MB, Kazerooni EA, Kelly AM, Scharf C, et al. (2004) MDCT of the left atrium and pulmonary veins in planning radiofrequency ablation for atrial fibrillation: a how-to guide. *AJR Am J Roentgenol* 183(3): 767-778.
2. Cho Y, Lee W, Park EA, Oh IY, Choi EK, et al. (2012) The anatomical characteristics of three different endocardial lines in the left atrium: evaluation by computed tomography prior to mitral isthmus block attempt. *Europace* 14(8): 1104-1111.
3. Di Biase L, Burkhardt JD, Mohanty P, Sanchez J, Mohanty S, et al. (2010) Left atrial appendage: an underrecognized trigger site of atrial fibrillation. *Circulation* 122(2): 109-118.
4. Pritchett AM, Jacobsen SJ, Mahoney DW, Rodeheffer RJ, Bailey KR, et al. (2003) Left atrial volume as an index of left atrial size: a population-based study. *J Am Coll Cardiol* 41(6): 1036-1043.
5. Tsang TS, Abhayaratna WP, Barnes ME, Miyasaka Y, Gersh BJ, et al (2006) Prediction of cardiovascular outcomes with left atrial size: is volume superior to area or diameter? *J Am Coll Cardiol* 47(5): 1018-1023.
6. Di Biase L, Santangeli P, Anselmino MJ, Mohanty P, Salvetti I, et al. (2012) Does the left atrial appendage morphology correlate with the risk of stroke in patients with atrial fibrillation? Results from a multicenter study. *Am Coll Cardiol* 60(6): 531-538.
7. Klein AL, Murray RD, Grimm RA (2001) Role of transesophageal echocardiography-guided cardioversion of patients with atrial fibrillation. *J Am Coll Cardiol* 37(3): 691-704.
8. Toffanin G, Scarabeo V, Verlato R, De Conti F, Zampiero AA, et al. (2006) Transoesophageal echocardiographic evaluation of pulmonary vein anatomy in patients undergoing ostial radiofrequency catheter ablation for atrial fibrillation: A comparison with magnetic resonance angiography. *J Cardiovasc Med (Hagerstown)* 7(10): 748-752.
9. Marrouche NF, Martin DO, Wazni O, Gillinov AM, Klein A, et al. (2003) Phased-array intracardiac echocardiography monitoring during pulmonary vein isolation in patients with atrial fibrillation. Impact on outcome and complications. *Circulation* 107(21): 2710-2716.
10. Heist EK, Chevalier J, Holmvang G, Singh JP, Ellinor PT, et al (2006) Factors affecting error in integration of electroanatomic mapping with CT and MR imaging during catheter ablation of atrial fibrillation. *J Interv Card Electrophysiol* 17(1): 21-27.
11. Noseworthy PA, Malchano ZJ, Ahmed J, Holmvang G, Ruskin JN, et al. (2005) The impact of respiration on left atrial and pulmonary venous anatomy: implications for image-guided intervention. *Heart Rhythm* 2(11): 1173-1178.
12. Jongbloed MR, Schalijs MJ, Zeppenfeld K, Oemrawsingh PV, van der Wall EE, et al. (2005) Clinical applications of intracardiac echocardiography in interventional procedures. *Heart* 91(7): 981-990.